CLINICAL ORAL IMPLANTS RESEARCH

C. Castellani
G. Zanoni
S. Tangl
M. van Griensven
H. Redl

Biphasic calcium phosphate ceramics in small bone defects: potential influence of carrier substances and bone marrow on bone regeneration

Authors' affiliations:
C. Castellani, Department of Paediatric Surgery, Medical University Graz, Graz, Austria
G. Zanoni, S. Tangl, M. van Griensven, H. Redl, Ludwig Boltzmann Institute for Experimental and Clinical Traumatology, Austrian Cluster of Tissue Engineering, Vienna, Austria
S. Tangl, Department of Oral Surgery, Bernhard Gottlieb University Dental Clinic, Medical University of Vienna, Vienna, Austria

Correspondence to:
Christoph Castellani
Department of Paediatric Surgery
Medical University Graz
Auenbruggerplatz 34
8036 Graz
Austria
Tel.: + 43 316 385 3762
Fax: + 43 316 385 3775
e-mail: christoph.castellani@medunigraz.at

Key words: bone grafts, bone marrow, Collagraft®, micro-computed tomography, TricOs T®

Abstract

Objectives: Synthetic calcium phosphate bone substitutes such as hydroxyapatite (HA), β-tricalcium phosphate (β-TCP) or mixtures are alternatives to autogenous bone grafts. TricOs T® and Collagraft® are resorbable bone substitutes consisting of biphasic calcium phosphate and a bioactive matrix. Both products have a similar HA to β-TCP ratio, but differ by their matrix. It was the aim of this study to determine the influence of matrix and autologous bone marrow on bone regeneration in a rabbit femoral condyle model.

Material and methods: A critical-sized bicortical channel with a diameter of 4.5 mm was drilled through the femoral condyles in male New Zealand rabbits. Collagraft® with bone marrow harvested from the posterior iliac crest or TricOs T® with and without bone marrow was introduced into the defect. Rabbits were euthanized 8 weeks later. The percentage of newly formed bone was determined by micro-computed tomography.

Results: There was no significant difference between bone ingrowth at 8 weeks. Thus, TricOs T® without bone marrow showed similar bone ingrowth as Collagraft® with bone marrow. Furthermore, no increase of bone ingrowth could be achieved by adding bone marrow to TricOs T® in the present setting.

Conclusion: Both bone substitutes showed similar bone ingrowth in this investigation. Using TricOs T® without bone marrow could avoid donor site morbidity due to harvesting of bone marrow. Further prospective clinical trials will be needed to investigate this approach.

Pseudoarthrosis, tumor-resection, osteomyelitis and traumatic bone loss are major causes for the occurrence of bone defects. These are still one of the most challenging problems in orthopedic and trauma surgery (Goshima et al. 1991; Rodriguez-Merchan & Forriol 2004; Jeon et al. 2006). With 250,000–500,000 surgeries per year involving bone grafts in the United States, there is an increasing demand for materials to aid the repair process of such defects (Goshima et al. 1991; Lane et al. 1999; Leupold et al. 2006). Fresh autologous bone grafts, commonly harvested at the iliac crest, are the therapy of choice (Cornell et al. 1991; Le Guehennec et al. 2004; Jones et al. 2005; Leupold et al. 2006). This graft provides optimal osteogenic, osteoconductive and osteoinductive properties (Leupold et al. 2006). However, major donor-site complications have been reported in 10–39% of the cases (Younger & Chapman 1989; Arrington et al. 1996). Additionally, the amount of autologous bone available is limited, which poses a problem in case of larger defects (Behairy & Jasty 1999).

As an alternative, allografts are easier to obtain and are not associated with donor-site morbidity (Leupold et al. 2006). Compared with autografts, special processing is

Date:
Accepted 12 May 2009

To cite this article:
Castellani C, Zanoni G, Tangl S, van Griensven M, Redl H. Biphasic calcium phosphate ceramics in small bone defects: potential influence of carrier substances and bone marrow on bone regeneration.
Clin. Oral Impl. Res. **20**, 2009; 1367–1374.
doi: 10.1111/j.1600-0501.2009.01760.x

necessary to eliminate cells and prevent transmission of infectious diseases (Stevenson & Horowitz 1992; Behairy & Jasty 1999; Boyce et al. 1999; Bauer & Muschler 2000). Delayed vascularization of these grafts is an additional disadvantage compared with autologous bone (Behairy & Jasty 1999; Boyce et al. 1999). Furthermore, storage of biological grafts is associated with various problems like risk of contamination and infection (Tomford et al. 1981; Hofmann et al. 1996; Farrington et al. 1998). These complications and limited availability have led to the development of various synthetic bone grafting substitutes (BGS) (Stevenson & Horowitz 1992; Bauer & Muschler 2000; Leupold et al. 2006). Mainly, natural corals, algae, demineralized bone substance and calcium phosphate derivatives have been advocated (Stevenson & Horowitz 1992; Le Guehennec et al. 2004). All of these materials are biocompatible, biodegradable and osteoconductive (Le Guehennec et al. 2004). They are mostly believed to have a low osteoinductive potential (Le Guehennec et al. 2004). An additional osteogenic component can be introduced by seeding these BGS with autologous stem cells, commonly in the form of bone marrow (Lane et al. 1999; Lieberman et al. 1999).

Synthetic calcium phosphate bone substitutes such as hydroxyapatite (HA), tricalcium phosphate (TCP) and biphasic calcium phosphates (sintered HA and β-TCP) have excellent biocompatibility and are common alternatives to autologous bone (Tadic & Epple 2004). They mainly differ with respect to their solubility or dissolution rate in acidic buffers, which may reflect their degradation *in vivo* (Le Guehennec et al. 2004). Overall, β-TCP ceramics are faster degradable than those of HA (Lu et al. 2002; Tadic & Epple 2004) or HA/β-TCP composites (Bodde et al. 2007). Examinations by Tadic and colleagues showed that synthetic BGS containing mainly β-TCP had a lower mechanical stability than those containing HA (Tadic & Epple 2004). Therefore, a combination of HA and β-TCP in form of biphasic calcium phosphate leads to a BGS with higher stability and lower degradability than β-TCP alone. Furthermore, investigations by Ng et al. (2007) proved that early bone formation was superior for β-TCP/HA composites compared to HA alone in an ectopic nude mouse model. From these data, the authors conclude that β-TCP and HA are the materials of choice in bone tissue engineering.

TricOs T® is a resorbable bone substitute consisting of a bioactive fibrin matrix (TISSEEL®) and particles of inorganic calcium phosphate (macroporous biphasic calcium phosphate, MBCP™). MBCP™ consists of sintered HA and β-TCP in a 60/40 ratio with an overall porosity of 80%. The material has a macro-porosity (pore diameter 300–600 μm) of 50–55% and a micro-porosity (pore diameter <10 μm) of 30–35%. Recently, many animal experiments have been conducted to evaluate combinations of calcium phosphates and fibrin (Kania et al. 1998; Cunin et al. 2000; Perka et al. 2000; Carmagnola et al. 2002). Clinical trials mainly dealt with the application of TricOs T® in craniomaxillofacial surgery (Bagot D'arc & Daculsi 2003; Le Guehennec et al. 2004).

Collagraft® contains purified lyophilized bovine dermal collagen (>95% collagen I and <5% collagen III) as an organic matrix and biphasic calcium phosphate [sintered HA (65%) and β-TCP (35%)] in a solid strip. Collagraft® has an overall porosity of 70%, with an average pore size of 26 μm (Lee et al. 2006). In addition to various animal studies, a prospective, randomized clinical multicentre trial showed similar results of Collagraft® in combination with an autologous bone marrow compared to autologous bone grafts (iliac crest) in long bone fractures after 6 and 12 months (Cornell et al. 1991).

Both products show almost similar HA/TCP ratio and overall porosity, but differ by pore size and matrix (fibrin vs. collagen). Up to now, these third-generation synthetic BGS have never been directly compared. Therefore, it was the aim of this study to determine possible differences in bone ingrowth between TricOs T® and Collagraft® in a critical-sized femoral condyle model in New Zealand white rabbits. It was of particular interest to investigate, whether Collagraft®, which is routinely used in combination with bone marrow, was equivalent to TricOs T®, which can also be used without bone marrow. Finally, it was examined whether the combination of biphasic phosphates and fibrin as present in TricOs T® further enhances osteogenesis by addition of bone marrow. This has not been tested before.

Material and methods

Forty-eight male New Zealand rabbits (Harlan-Winkelmann, Borchen, Germany) were included in this prospective, controlled evaluation blinded preclinical study. The study was approved by the local legislative committee according to the national law. The mean weight of the animals at the day of operation ranged from 3.23 to 4.24 kg.

Surgical procedure

After randomization into five different groups (Table 1), the rabbits were anesthetized by a subcutaneous injection of 60 mg/kg body weight ketamine (Ketavet®, Pharmacia GmbH, Erlangen, Germany) and 16 mg/kg xylazine (Rompun®, Bayer AG, Leverkusen, Germany). Anesthesia was maintained by an intravenous administration of thiopental sodium (Thiopental®, Biochemie GmbH, Kundl, Austria). In the groups using bone marrow, both the hind legs and the area of the right iliac crest were shaved and the skin was disinfected with Betaisodona® solution (Mundipharma GmbH, Limburg, Germany). Analogous to the literature, the iliac bone at the posterior cranial iliac crest was prepared using a 3 cm skin incision (Minamide et al. 2005). The bone was punctured with a 2 × 30 mm

Table 1. **Group set-up and bone graft material ($n = 48$ animals with bilateral operation)**

Group	*n*	Therapy	Euthanasia
Experimental 1	8	TricOs T®	8 weeks
Experimental 2	8	TricOs T® + bone marrow	8 weeks
Experimental 3	8	Collagraft® + bone marrow	8 weeks
Reference 1	10	Reference group, TricOs T®	Immediately post OP
Reference 2	10	Reference group, Collagraft® + bone marrow	Immediately post OP
Control	4	Drill hole only, no therapy	8 weeks

needle. One milliliter of bone marrow was aspirated to 5 ml syringes rinsed with 1000 IU/ml Heparin (Heparin 1000 IU/ml®, Baxter AG, Vienna, Austria). The bone marrow was stored at 37°C until preparation of the bone grafting substances. Subsequently, the skin incision was sutured with Synthofil® 2.0 (B. Braun Melsungen AG, Melsungen, Germany) using interrupted sutures.

After lateral skin incision, the lateral femoral condyle was prepared on both hind legs in all animals. A single bicortical critical-sized channel with a diameter of 4.5 mm was drilled slightly proximal of the joint capsule's insertion perpendicular to the shaft axis. The drilling process was performed under constant irrigation with sterile physiologic saline solution. Meanwhile, bone grafting materials were prepared. Both drill holes (one per hind leg) were filled with the same bone grafting material, leading to two specimens per animal.

Study groups

TricOs T® (Baxter Healthcare S.A.): Granules with a diameter of 1–2 mm were used. TricOs T® was prepared according to the manufacturer's instructions. Fibrin sealant (FS) (TISSEEL®, Baxter AG) was mixed using two solutions according to the manufacturer's instruction. Solution 1 contained 2 ml of lyophilized sealer protein reconstituted in 2 ml of 3000 IU/ml aprotinin solution. For solution 2, 0.1 ml of 500 IU/ml lyophilized thrombin was mixed with 0.9 ml physiological saline. 0.1 ml of this solution was mixed with 0.9 ml of 40 μmol/ml calcium chloride solution to obtain a concentration of 5 IU/ml thrombin. Then 2 g of MBCP™ granules (prefilled in a syringe) were mixed with either 1 ml of sterile water (experimental group 1) or 1 ml of autologous bone marrow (experimental group 2) according to the manufacturer's instructions. In a final step, 2 ml TISSEEL® (1 ml fibrinogen + 1 ml thrombin solution) were added to the syringe. Then the defect was completely filled with the mixture by injection (approximately 300 μl).

Collagraft® (Zimmer Inc., Warsaw, IN, USA): Collagraft® was prepared according to the manufacturer's instructions. 100 mm² of the Collagraft® strip (20 × 5 mm) was hydrated in physiological sodium chloride for 3 min. Upon complete rehydration, the strip was covered with 0.2 ml autologous bone marrow (experimental group 3) and press fit to the channel. Subsequently, Synthofil® 2.0 was used for stepwise wound closure.

Control and reference groups

After removing loose bone particles by vigorously rinsing, bone grafting materials were introduced into the channel according to group allocation (Jiang et al. 2005). These two groups (reference groups 1 + 2) were essential for calibration of the micro-computed tomography (μCT). Additionally, a group with a drill hole only (control group) was included as control group. As in the study groups wounds were closed with Synthofil® 2.0.

In the experimental and control groups, a 20 mg/kg body weight tetracycline (Terramycine with PVP®, Pfizer Corp., Vienna, Austria) was administered postoperatively for single-shot antibiotic therapy. Thereafter, the animals were kept in separate cages and provided with water and food (Ssniff® K-H Alleindiaet for rabbits, Ssniff, Soest, Germany) *ad libitum*. Unrestricted activity was permitted immediately after surgery.

Preparation of specimens

Depending on group allocation, the rabbits were euthanized either directly after implantation of the bone grafting materials (reference groups 1 + 2) or 8 weeks postoperatively (experimental and control groups). Euthanasia was always performed under general anesthesia (Ketamine and Rompun, doses see above) by an overdose (approximately 320 mg) of intravenous thiopental sodium. Immediately, the distal femur (epi- and metaphysis) was removed bilaterally. In the reference groups, drilling channels were sealed with conventional superglue (Loctite®, Henkel Central Eastern Europe GmbH, Vienna, Austria) to prevent loss of implant material. Specimens were fixed in buffered 4.5% formaldehyde solution (Neuber GmbH, Guntramsdorf, Austria) for at least 1 week. A bicortical bone cylinder with a diameter of 15 mm including the transosseus channel containing the grafting material was removed from each femur with a hollow bone biopsy drill. The cylinder was again stored in 4.5% formaldehyde solution until measurement.

μCT

Both hind legs of all animals were examined. All analyses were performed by μCT (MicroCT 20, Scanco Medical, Basersdorf, Switzerland) in a measurement vial. From each specimen, 450 slices with a thickness of 17 μm were obtained in high-resolution mode and 150 ms integration time (one voxel had a volume of 17 × 17 × 17 μm). As scan slices were oriented perpendicular to the long axis of the original drill channel, the augmented region appeared as a round area containing the respective bone substitute materials (Fig. 1). A circular region of interest with a diameter that equalled the original drill hole (4.5 mm or 265 pixels) was placed over the defect and defined as area of measurement per slice (Fig. 1c). In order to obtain a higher degree of standardization, slices near the cortical bone were excluded from the evaluation, because the mode and rate of bone formation is more stochastic and less predictable there than in the cancellous part of the metaphysis. Accordingly, out of 450 slices obtained, only

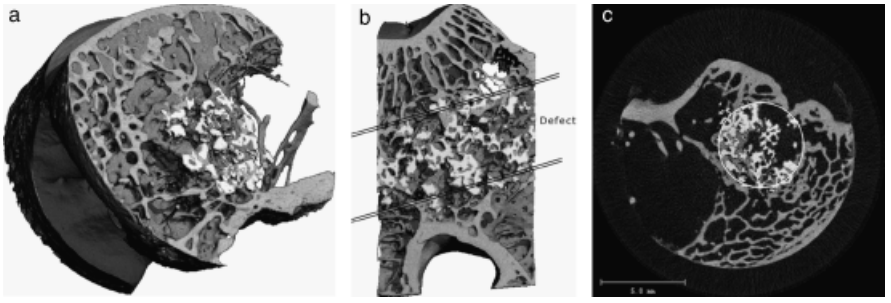

Fig. 1. (a) Three-dimensional (3D) reconstruction of a rabbit distal femur; (b) 3D reconstruction with a defect; the drill hole filled with bone substitute material and newly formed bone is marked by the two parallel lines; (c) representative slice as obtained by micro-computed tomography analysis; the circle marks the defect as the area of interest.

slice numbers 100–350 (250 slices), equalling the center of the defect, were selected for further calculations.

To distinguish between the different materials contained in the defect, different thresholds had to be set (Table 2). The digitalized data were analyzed using the built-in software of the μCT. The volume of calcified tissue (CV_{low}; newly formed bone plus grafting material) per tissue volume (TV) was calculated. To eliminate grafting material and calculate the amount of newly formed bone volume (BV) per TV the results of the higher threshold (CV_{high}; representing the grafting material only) had to be subtracted from those of the lower threshold (bone plus implant). Thresholds are displayed as subscripts in the formulas below:

$$BV/TV_{8\,weeks} = CV_{low}/TV - CV_{high}/TV$$

To correct for false-positive newly formed bone (due to edge effects or noise), the mean values of $BV/TV_{0\ weeks}$ of the reference groups were calculated as follows:

$$BV/TV_{0\,weeks} = CV_{low}/TV - CV_{high}/TV$$

This was essential in order to calculate the final amount of newly formed bone per free available space (NB/FS) at 8 weeks. Therefore, the mean at 0 weeks had to be subtracted from the BV/TV values at 8 weeks.

$$NB/FS = BV/TV_{8\,weeks} - \text{mean}(BV/TV_{0\,weeks})$$

Histological methods

After μCT evaluation, from each of the experimental groups (1–3) one specimen was chosen for histological preparation. After fixation in formaldehyde solution, dehydration was performed by ethanol series with ascending concentrations (from 50% to 100%). After plastic embedding ground thin sections were produced as described by Donath (1988) and stained according to Levai–Laczko. The slides were photographed using a digital camera (Nikon DXM 1200, Nikon Corporation, Tokyo, Japan) mounted on a light microscope (Nikon Microphot-FXA, Nikon Corporation).

Statistical methods

All statistical calculations were performed with SAS 8.2® for Linux (SAS Institute Inc., Cary, NC, USA). Arithmetic means and standard errors were calculated for the new bone as well as for the new bone per implant material for each group. For means of the new bone and of the new bone per implant material, 95% bootstrap-t confidence intervals were calculated from 100,000 re-samples for each group (Efron & Tibshirani 1993). The new bone as well as the new bone per implant material was compared pairwise between the three groups. The comparisons were tested using the SAS procedure MULTTEST (SAS Institute Inc., Cary, NC, USA). Unadjusted two-sided *P*-values (raw *P*-values) were obtained from *t*-tests of the mean with 1,000,000 bootstrap re-samples. For testing these three comparisons, simultaneously adjusted two-sided *P*-values were obtained from 1,000,000 bootstrap re-samples for the new bone as well as for the new bone per implant material. The level of statistical significance was set to 5% for the adjusted *P*-values.

Table 2. **Thresholds as visually selected in the evaluation of the micro-computed tomography**

Threshold	Material measured	Groups
320 (low)	Bone + Implant material	All groups
500 (high)	Implant material (TricOs T®)	Experimental 1 + 2
480 (high)	Implant material (Collagraft®)	Experimental 3
400 (high)	Implant material (TricOs T®)	Reference 1
380 (high)	Implant material (Collagraft®)	Reference 2

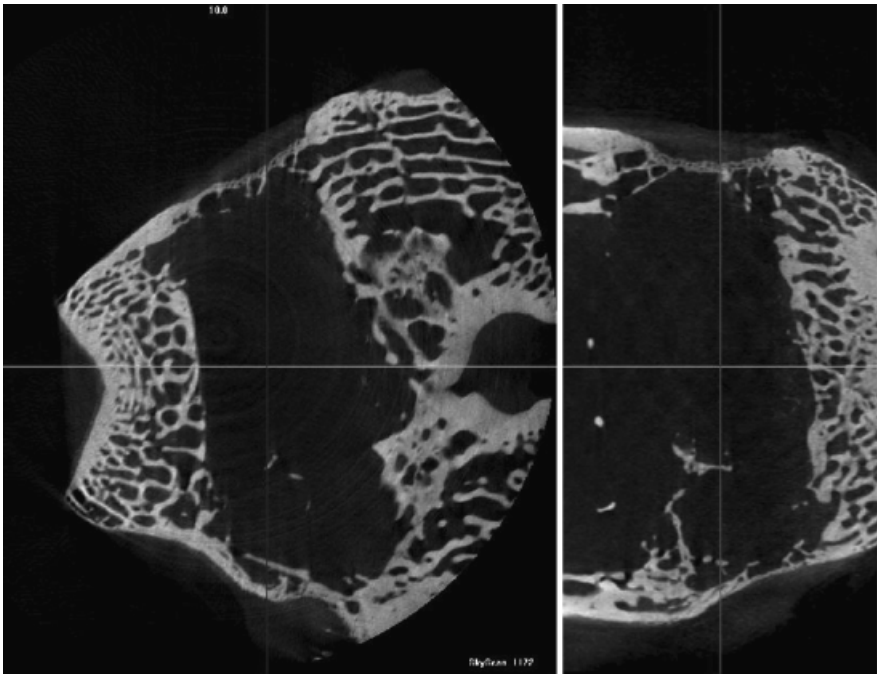

Fig. 2. Micro-computed tomography scan of a femur from the control group after 8 weeks. No newly formed bone within the drill channel.

Results

Control group

Of four animals with eight bones operated with drill holes, six bones showed no bone formation in the defect (Fig. 2). In another two femura, minimal bone formation could be observed.

Experimental groups

There were no statistically significant differences between the groups regarding bone ingrowth in the μCT after 8 weeks. The new bone per free available space (NB/FS) at 8 weeks was the highest for TricOs T® with bone marrow (experimental group 2; mean 12.29, standard deviation 2.93, 95% CI for mean 10.67–13.91), followed by TricOs T® without bone marrow (experimental group 1; mean 11.85, standard deviation 3.16, 95% CI for mean 10.11–13.6) and Collagraft® with bone marrow (experimental group 3; mean 10.9, stan-

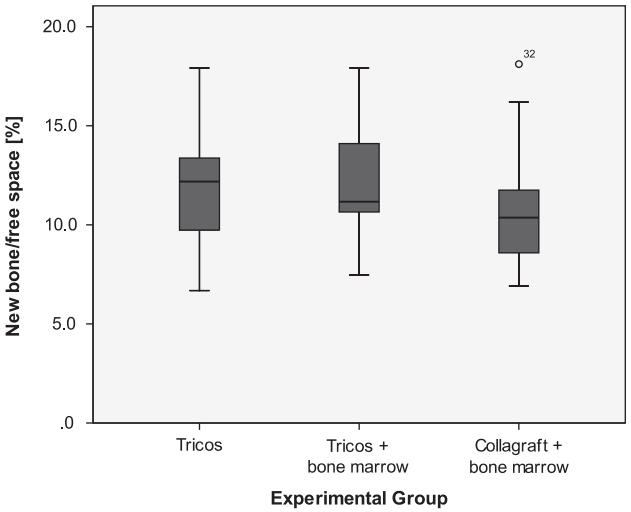

Fig. 3. Newly formed bone per free available space (NB/FS) in experimental groups 1–3 ($n = 16$ bones of eight animals per group). Box: first quartile, median and third quartile, whiskers: minimum and maximum excluding outliers. Outliers are automatically calculated by SPSS® software, shown as a circle and marked with the ID number of the animal.

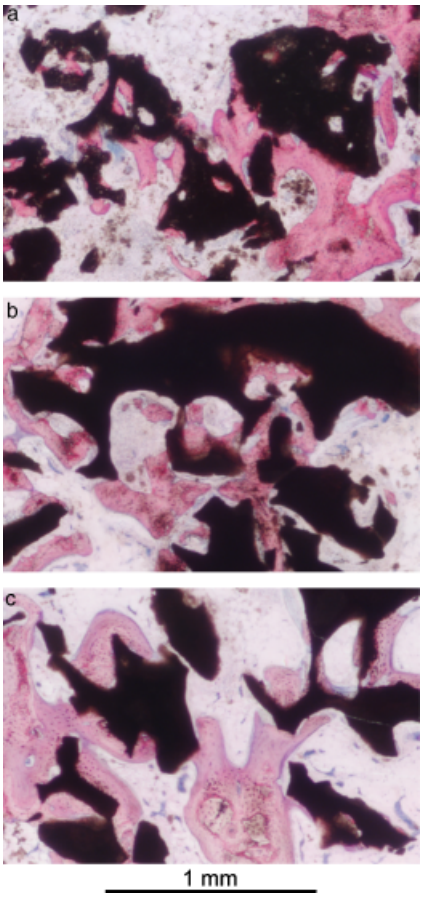

Fig. 4. Bone formation on the surfaces and interparticular spaces of the experimental groups. Plastic-embedded, undecalcified ground thin sections, Levai–Laczko stain; bone is stained pink and BGS black. (a) Collagraft®; (b) TricOs T® without the addition of bone marrow and (c) TricOs T® with bone marrow. The amount of newly formed bone and its distribution is similar for all three groups. Bone is in direct contact with the surface of the substitute materials without an intermediate layer of soft tissue, thereby demonstrating good ossseointegrative properties. For all three groups, mostly woven bone that has been compacted with lamellar bone has been formed, i.e. bone quality is practically identical. No obvious differences in the presence of resorptive or osteoblastic processes can be detected.

dard deviation 3.15, 95% CI for mean 9.21–12.58) (Fig. 3). The following results were obtained by bootstrap analysis at 8 weeks: experimental group 1 vs. 2, $P = 0.9212$; experimental group 1 vs. 3, $P = 0.666$; experimental group 2 vs. 3, $P = 0.4276$. Thus, TricOs T® without bone marrow showed similar results as Collagraft® with bone marrow. Furthermore, adding bone marrow to TricOs T® did not lead to a further increase of bone ingrowth. In the histological sections (Fig. 4) the amount of newly formed bone and its distribution was similar for all three groups.

Discussion

The presented project evaluated bone ingrowth and thus regenerative potential in a metaphyseal small bone defect filled with bone grafting substances mainly differing by their matrix. Collagraft® was only used in combination with bone marrow (according to the manufacturer's instructions). TricOs T® was used with and without bone marrow to assess its influence on the healing process. The bone ingrowth 8 weeks after implantation was determined by μCT and calibrated by a comparison with baseline values determined immediately after operation were obviously no formation of new bone could have taken place. After 8 weeks no significant differences could be observed between the three groups. Thus, the different matrix of the two BGS had no significant influence on bone regeneration in the presented defect model. Furthermore, bone marrow did not increase bone ingrowth when combined with TricOs T®.

Specimen and bone model

Male white New Zealand rabbits were chosen because of the ease of handling and the anatomical characteristics of their distal femur (Leupold et al. 2006). The initial weight of the animals in this project is similar to other reports (Leupold et al. 2006). Previous studies already proved the femoral condyle as a good model for the evaluation of bone substitutes. In this project the authors aimed to create a critical-sized bone defect and drilled a transcortical 4.5-mm-diameter drill channel through the distal femur. Most other authors used monocortical drill holes with a diameter of 4.5–8 mm and a length of 6.5–10 mm (al Ruhaimi 2000; Hoshikawa et al. 2003; Hing et al. 2005; Jegoux et al. 2005), and there are several reports about even these smaller defects being critical sized at time points similar to ours (Le Guehennec et al. 2004; Rimondini et al. 2005; Erli et al. 2006; Soffer et al. 2006). As even monocortical defects with a diameter of 4 mm were reported to be critical sized, our model seems to be appropriate although a direct comparison is not possible. Furthermore, the model could be validated as critical size by the lack of bone ingrowth seen in the control groups at the investigated endpoints.

The time of euthanasia chosen for this project was close to reports by other authors (al Ruhaimi 2000; Jegoux et al. 2005; Leupold et al. 2006), but earlier than the one chosen by others (Hoshikawa et al. 2003; Hing et al. 2005). As bony ingrowth and not degradation of the BGS was the focus of this project, 8 weeks were chosen for euthanasia.

Bone grafting substances

Hemostasis (Le Guehennec et al. 2004) and the clotting effects gluing particles to each other and the implantation site (Jegoux et al. 2005) are the handling advantages of combining biphasic calcium phosphate with FS (TricOs T®). However, the effects of compounds containing FS to bone healing are controversially discussed in the literature. Carmagnola et al. (2002) observed negative effects of FS in combination with a bovine bone graft in the alveolar bone of Labrador dogs. They attribute their findings to the FS and speculate that it causes impaired early vascularization and thus reduced bone ingrowth. Injecting coral granules with or without FS in vertebral bodies of sheep, Cunin et al. (2000) report significantly lower bone formation for the composite compared with coral granules alone. The authors speculate that FS may prevent the invasion of osteoprogenitor cells. Additionally, they assume that FS might lead to chemotaxis and inflammation rather than bone formation.

These findings contradict reports of Kania et al. (1998), who demonstrated enhanced bone formation for a coral granule and FS composite compared with coral granules only. Similarly, Perka et al. (2000) showed (histologically and radiologically) a higher bone formation for fibrin or poly-lacto-glucolite seeded with isolated periostal cells in comparison to the carrier alone in a rabbit ulnar defect model. The promising data reported in animal experiments encouraged various clinical trials showing enhanced bone formation for FS and ceramic biomaterial composites (Bagot D'arc & Daculsi 2003; Le Guehennec et al. 2004). One of the possible reasons for the controversial results in the literature could be found in the varying ratios between fibrin and particle material, which was optimized for the trial presented here.

Similar to TricOs T®, Collagraft® consists of HA and β-TCP in an organic matrix. Although the HA/TCP ratio and overall porosity are very similar in both BGS they differ in the matrix used. At present, there is no further information about the exact physico-chemical differences or similarities between these BGS. However, we think that these data are of minor importance for the comparison this project was focused on. The bovine collagen fibers used as matrix in Collagraft® represent the major difference from TricOs T®. In a rabbit femoral condyle model, Collagraft® showed significantly higher bone ingrowth compared with ProOsteon® (ceramic) and DBX® (demineralized bone matrix) ($P = 0.046$) (Leupold et al. 2006). Similarly, a prospective, randomized clinical multicenter trial revealed identical results of Collagraft® in combination with autologous bone marrow compared with autologous bone grafts (iliac crest) (Cornell et al. 1991).

As directed in the manufacturer's instructions, Collagraft® was used in combination with autologous bone marrow. During application of the material, crumbling was observed in some cases, which is consistent with data published in the literature (Leupold et al. 2006) but seemed to be without effect on the results.

Additionally, a combination of TricOs T® and autologous bone marrow was tested in a third group to investigate its influence on bone ingrowth. In a pilot study, the total amount of bone marrow was calculated in such a way as to assure similar volumes (about 0.2 ml) per defect channel in the Collagraft® and the TricOs T® group.

FS forms the organic matrix of TricOs T®. Typically, FS contain bovine aprotinin or synthetic tranexamic acid (t-AMCA) as antifibrinolytic agents to prevent premature resorption of the fibrin clot (Pipan et al. 1992). Although an experimental trial showed that the kind of antifibrinolytic agent had no influence on bone ingrowth (Jegoux et al. 2005), other authors report adverse effects of t-AMCA compared with aprotinin (Furst et al. 2007).

Test results

μCT allows non-destructive examination of materialized bone samples, similar to a clinical CT but with a higher resolution (Ruegsegger et al. 1996). In recent publications, a significant correlation between μCT measurements, histological examinations (Muller et al. 1998) and biomechanical data (Schmidhammer et al. 2006) could be proven. In contrast to histology, commonly evaluating only a few slices per specimen, μCT has the advantage of analyzing many more slices throughout the defect (450, of which 250 were chosen for further calculation in the current study). This advantage of μCT was the reason why radiological data were chosen for group comparison in this project. Nevertheless, histological slides were obtained to gain an optical overview of the different BGS.

Examinations of μCT slices revealed a high intensity (high threshold) identifying implant material (granules) compared with a low intensity (gray values) of bone (low threshold) and thus allowed differentiation between bone and implant. Comparing higher thresholds at 0 and 8 weeks, a higher intensity for the granules was observed at 8 weeks. Thus, a different threshold had to be chosen. This phenomenon was attributed to a certain condensation of the granules over time. To minimize errors (noise, bone edges) results at 8 weeks were related to the reference groups. A direct comparison between Collagraft® with and without bone marrow was not performed, because Collagraft® is licensed to be used in combination with bone marrow only. There is also good reasoning to do so, because in contrast to fibrin (Sahni et al. 2004; Tonnesen et al. 2000) collagen does not contain growth factors and therefore depends on additional osteoinductive measures.

In this study, there was no significant difference in bone ingrowth between the experimental groups, but the number of specimens was too small to show formal bioequivalence (1–3) (Fig. 4). There was no significant difference between Collagraft® with bone marrow and TricOs T® without bone marrow. Furthermore, addition of bone marrow to TricOs T® did not lead to a significant increase of bone ingrowth in the current setting, which agrees with the results published in the literature (LeNihouannen et al. 2007). Analyzing the setup of this project, there might be two different reasons for the little effect of autologous bone marrow. Hematopoietically active red bone marrow and stem cells present in the distal femur might be the reason for the insignificant effect of additionally added bone marrow in this setting. Their activity may be so high that the amount of autologous bone marrow added to the constructs has no significant influence on bone ingrowth.

The presented results suggest that adding bone marrow to TricOs T® has no benefits concerning bone ingrowth (and fracture healing) in the current setting. Thus, harvesting of bone marrow is unnecessary when choosing TricOs T® as BGS in

lesions of the distal femur. If applicable to clinical conditions, this would reduce the operating time and resolve donor site morbidity associated with the harvesting process.

Conclusions

Both BGS tested showed similar good bone ingrowth in the metaphyseal small bone defect applied in this investigation. No significant differences could be found between the groups. TricOs T® showed similar bone ingrowth with and without autologous bone marrow. Thus, donor site morbidity could be avoided by using TricOs T® on its own. Further prospective clinical trials will be used to investigate this approach.

Acknowledgements: We wish to thank Elzbieta Brozek, Bernhard Höring, Gabriele Leinfellner, Paul Niedzielski, Sonja Reisinger, Manuela Simunek and Susanne Toifl for their excellent technical contributions to this project. This work was partially carried out under the scope of the European NoE 'Expertissue' (NMP3-CT-2004-500283). There was no conflict of interest for C.C., Z.G. and T.S.; M.G. and H.R. are consultants to Baxter Innovations Vienna.

References

al Ruhaimi, K.A. (2000) Effect of adding resorbable calcium sulfate to grafting materials on early bone regeneration in osseous defects in rabbits. *International Journal of Oral & Maxillofacial Implants* **15**: 859–864.

Arrington, E.D., Smith, W.J., Chambers, H.G., Bucknell, A.L. & Davino, N.A. (1996) Complications of iliac crest bone graft harvesting. *Clinical Orthopaedics and Related Research* **329**: 300–309.

Bagot D'arc, M. & Daculsi, G. (2003) Micro macroporous biphasic ceramics and fibrin sealant as a moldable material for bone reconstruction in chronic otitis media surgery. A 15 years experience. *Journal of Materials Science: Materials in Medicine* **14**: 229–233.

Bauer, T.W. & Muschler, G.F. (2000) Bone graft materials. An overview of the basic science. *Clinical Orthopaedics and Related Research* **371**: 10–27.

Behairy, Y. & Jasty, M. (1999) Bone grafts and bone substitutes in hip and knee surgery. *Orthopaedic Clinics of North America* **30**: 661–671.

Bodde, E.W., Wolke, J.G., Kowalski, R.S. & Jansen, J.A. (2007) Bone regeneration of porous beta-tricalcium phosphate (conduit tcp) and of biphasic calcium phosphate ceramic (biosel) in trabecular defects in sheep. *Journal of Biomedical Material Research Part A* **82A**: 711–722.

Boyce, T., Edwards, J. & Scarborough, N. (1999) Allograft bone. The influence of processing on safety and performance. *Orthopaedic Clinics of North America* **30**: 571–581.

Carmagnola, D., Berglundh, T. & Lindhe, J. (2002) The effect of a fibrin glue on the integration of bio-oss with bone tissue. A experimental study in labrador dogs. *Journal of Clinical Periodontology* **29**: 377–383.

Cornell, C.N., Lane, J.M., Chapman, M., Merkow, R., Seligson, D., Henry, S., Gustilo, R. & Vincent, K. (1991) Multicenter trial of collagraft as bone graft substitute. *Journal of Orthopaedic Trauma* **5**: 1–8.

Cunin, G., Boissonnet, H., Petite, H., Blanchat, C. & Guillemin, G. (2000) Experimental vertebroplasty using osteoconductive granular material. *Spine* **25**: 1070–1076.

Donath, K. (1988) Die trenn-dünnschliff-technik zur herstellung histologischer präparate von nicht schneidbaren geweben und materialien. *Der Praeparator* **34**: 197–206.

Efron, B. & Tibshirani, R.J. (1993) *An Introduction to the Bootstrap*. London, New York, Washington DC: Chapman & Hall/CRC.

Erli, H.J., Ruger, M., Ragoss, C., Jahnen-Dechent, W., Hollander, D.A., Paar, O. & von Walter, M. (2006) The effect of surface modification of a porous TiO2/perlite composite on the ingrowth of bone tissue in vivo. *Biomaterials* **27**: 1270–1276.

Farrington, M., Matthews, I., Foreman, J., Richardson, K.M. & Caffrey, E. (1998) Microbiological monitoring of bone grafts: two years' experience at a tissue bank. *Journal of Hospital Infection* **38**: 261–271.

Furst, W., Banerjee, A. & Redl, H. (2007) Comparison of structure, strength and cytocompatibility of a fibrin matrix supplemented either with tranexamic acid or aprotinin. *Journal of Biomedical Material Research Part B: Applied Biomaterials* **82B**: 109–114.

Goshima, J., Goldberg, V.M. & Caplan, A.I. (1991) Osteogenic potential of culture-expanded rat marrow cells as assayed in vivo with porous calcium phosphate ceramic. *Biomaterials* **12**: 253–258.

Hing, K.A., Annaz, B., Saeed, S., Revell, P.A. & Buckland, T. (2005) Microporosity enhances bioactivity of synthetic bone graft substitutes. *Journal of Materials Science: Materials in Medicine* **16**: 467–475.

Hofmann, C., von Garrel, T. & Gotzen, L. (1996) Bone bank management using a thermal disinfection system (lobator SD-1). A critical analysis. *Unfallchirurg* **99**: 498–508.

Hoshikawa, A., Fukui, N., Fukuda, A., Sawamura, T., Hattori, M., Nakamura, K. & Oda, H. (2003) Quantitative analysis of the resorption and osteoconduction process of a calcium phosphate cement and its mechanical effect for screw fixation. *Biomaterials* **24**: 4967–4975.

Jegoux, F., Goyenvalle, E., Bagot D'arc, M., Aguado, E. & Daculsi, G. (2005) In vivo biological performance of composites combining micro-macroporous biphasic calcium phosphate granules and fibrin sealant. *Archives of Orthopaedic Trauma Surgery* **125**: 153–159.

Jeon, D.G., Kim, M.S., Cho, W.H., Song, W.S. & Lee, S.Y. (2006) Pasteurized autograft for intercalary reconstruction: an alternative to allograft. *Clinical Orthopaedics and Related Research* **456**: 203–210.

Jiang, Y., Zhao, J., Liao, E.Y., Dai, R.C., Wu, X.P. & Genant, H.K. (2005) Applikation of micro-CT assessment of 3-D bone microstructure in preclinical and clinical studies. *Journal of Bone and Mineral Metabolism* **23**: 122–131.

Jones, S., Batchelor, M., Bhelt, D., Clarke, A.R., Collinge, J. & Jackson, G.S. (2005) Recombinant prion protein does not possess SOD-1 activity. *Biochemical Journal* **392**: 309–312.

Kania, R.E., Meunier, A., Hamadouche, M., Sedel, L. & Petite, H. (1998) Addition of fibrin sealant to ceramic promotes bone repair: long-term study in rabbit femoral defect model. *Journal of Biomedical Material Research* **43**: 38–45.

Lane, J.M., Yasko, A.W., Tomin, E., Cole, B.J., Waller, S., Browne, M., Turek, T. & Gross, J. (1999) Bone marrow and recombinant human bone morphogenetic protein-2 in osseous repair. *Clinical Orthopaedics and Related Research* **361**: 216–227.

Lee, S.J., Lim, G.J., Lee, J.-W., Atala, A. & Yoo, J.J. (2006) In vitro evaluation of a poly(lactide-co-glycolide)–collagen composite scaffold for bone regeneration. *Biomaterials* **27**: 3466–3472.

Le Guehennec, L., Goyenvalle, E., Aguado, E., Houchmand-Cuny, M., Enkel, B., Pilet, P., Daculsi, G. & Layrolle, P. (2004) Small-animal models for testing macroporous ceramic bone substitutes. *Journal of Biomedical Material Research Part B: Applied Biomaterials* **72B**: 69–78.

Le Guehennec, L., Layrolle, P. & Daculsi, G. (2004) A review of bioceramics and fibrin sealant. *European Cells and Materials Journal* **8**: 1–10.

LeNihouannen, D., Goyenvalle, E., Aguado, E., Pilet, P., Bilban, M., Daculsi, G. & Layrolle, P. (2007) Hybrid composites of calcium phosphate granules, fibrin glue, and bone marrow for skeletal repair. *Journal of Biomedical Material Research Part A* **81A**: 399–408.

Leupold, J.A., Barfield, W.R., An, Y.H. & Hartsock, L.A. (2006) A comparison of proosteon, DBX, and collagraft in a rabbit model. *Journal of Biomedical Material Research Part B: Applied Biomaterials* **79B**: 292–297.

Lieberman, J.R., Daluiski, A., Stevenson, S., Wu, L., McAllister, P., Lee, Y.P., Kabo, J.M., Finerman, G.A., Berk, A.J. & Witte, O.N. (1999) The effect of regional gene therapy with bone morphogenetic protein-2-producing bone-marrow cells on the repair of segmental femoral defects in rats. *Journal*

of Bone and Joint Surgery, American Edition **81A**: 905–917.

Lu, J., Descamps, M., Dejou, J., Koubi, G., Hardouin, P., Lemaitre, J. & Proust, J.P. (2002) The biodegradation mechanism of calcium phosphate biomaterials in bone. *Journal of Biomedical Material Research* **63**: 408–412.

Minamide, A., Yoshida, M., Kawakami, M., Yamasaki, S., Kojima, H., Hashizume, H. & Boden, S.D. (2005) The use of cultured bone marrow cells in type I collagen gel and porous hydroxyapatite for posterolateral lumbar spine fusion. *Spine* **30**: 1134–1138.

Muller, R., Van Campenhout, H., Van Damme, B., van der Perre, G., Dequeker, J., Hildebrand, T. & Ruegsegger, P. (1998) Morphometric analysis of human bone biopsies: a quantitative structural comparison of histological sections and micro-computed tomography. *Bone* **23**: 59–66.

Ng, A.M., Tan, K.K., Phang, M.Y., Aziyati, O., Tan, G.H., Isa, M.R., Aminuddin, B.S., Naseem, M., Fauziah, O. & Ruszymah, B.H. (2007) Differential osteogenic activity of osteoprogenitor cells on HA and TCP/HA scaffold of tissue engineered bone. *Journal of Biomedical Material Research Part A* **85A**: 301–312.

Perka, C., Schultz, O., Spitzer, R.S., Lindenhayn, K., Burmester, G.R. & Sittinger, M. (2000) Segmental bone repair by tissue-engineered periosteal cell transplants with bioresorbable fleece and fibrin scaffolds in rabbits. *Biomaterials* **21**: 1145–1153.

Pipan, C.M., Glasheen, W.P., Matthew, T.L., Gonias, S.L., Hwang, L.J., Jane, J.A. & Spotnitz, W.D. (1992) Effects of antifibrinolytic agents on the life span of fibrin sealant. *Journal of Surgical Research* **53**: 402–407.

Rimondini, L., Nicoli-Aldini, N., Fini, M., Guzzardella, G., Tschon, M. & Giardino, R. (2005) In vivo experimental study on bone regeneration in critical bone defects using an injectable biodegradable PLA/PGA copolymer. *Oral Surgery, Oral Medicine, Oral Pathology, Oral Radiology & Endodontics* **99**: 148–154.

Rodriguez-Merchan, E.C. & Forriol, F. (2004) Nonunion: general principles and experimental data. *Clinical Orthopaedics and Related Research* **419**: 4–12.

Ruegsegger, P., Koller, B. & Muller, R. (1996) A microtomographic system for the nondestructive evaluation of bone architecture. *Calcified Tissue International* **58**: 24–29.

Sahni, A., Guo, M., Sahni, S.K. & Francis, C.W. (2004) Interleukin-1b but not IL-1a binds to fibrinogen and fibrin and has enhanced activity in the bound form. *Blood* **104**: 409–414.

Schmidhammer, R., Zandieh, S., Mittermayr, R., Pelinka, L.E., Leixnering, M., Hopf, R., Kroepfl, A. & Redl, H. (2006) Assessment of bone union/nonunion in an experimental model using micro-computed technology. *Journal of Trauma* **61**: 199–205.

Soffer, E., Ouhayoun, J.P., Meunier, A. & Anagnostou, F. (2006) Effects of autologous platelet lysates on ceramic particle resorption and new bone formation in critical size defects: the role of anatomical sites. *Journal of Biomedical Material Research Part B: Applied Biomaterials* **79B**: 86–94.

Stevenson, S. & Horowitz, M. (1992) The response to bone allografts. *Journal of Bone and Joint Surgery, American Edition* **74A**: 939–950.

Tadic, D. & Epple, M. (2004) A thorough physicochemical characterisation of 14 calcium phosphate-based bone substitution materials in comparison to natural bone. *Biomaterials* **25**: 987–994.

Tomford, W.W., Starkweather, R.J. & Goldman, M.H. (1981) A study of the clinical incidence of infection in the use of banked allograft bone. *Journal of Bone and Joint Surgery, American Edition* **63A**: 244–248.

Tonnesen, M.G., Feng, X. & Clark, R.A. (2000) Angiogenesis in wound healing. *Journal of Investigative Dermatolology Symposium Proceedings* **5**: 40–46.

Younger, E.M. & Chapman, M.W. (1989) Morbidity at bone graft donor sites. *Journal of Orthopaedic Trauma* **3**: 192–195.