Bone ingrowth for Sinus lift augmentation with Micro Macroporous Biphasic Calcium Human cases evaluation using microCT and histomorphometry

Nicolas Mailhac[1], Daculsi G. [2, 3]
1 – Clinique Dentaire, 5 rue du 22 ème BMNA. 71400 AUTUN
- Nantes University ERT 1051, Faculty of dental Surgery, Place A. Ricordeau, 44042 Nantes
3 - INSERM CIC, Bordeaux Hospital, France

n.mailhac@wanadoo.fr, guy.daculsi@univ-nantes.fr; francoisemoreau@biomatlante.com

Abstract

The development of implantology requires enough bone support, sufficient bone architecture. The use of autograft remains the gold standard; however the surgeons use cortical bone coming from mandibular part or craniofacial site, involving severe anaesthetic bone loss. The strategy of bone substitutes in place of autograft can be an efficient method. Several patients having a sinus lift augmentation using MBCP, and BioOss have been performed in human, and bone biopsies were realized during the preparation of the site for dental implantation. Biopsies were analyzed in classical histology without decalcification and by 3D reconstruction using micro CT. Both techniques revealed bone ingrowth and MBCP resorption. For BioOss, no bone ingrtowth and resorption process were observed in spite of stability of the implant and clinical efficiency. These case reports confirm the performance of bone substitutes for Sinus Lift augmentation.

Introduction

Among the available materials used for pre-implant bone reconstruction, autologous bone is currently the gold-standard because it is a source of osseous matrix, cells, and growth modulating molecules [1]. However, it requires the graft to be harvested at a distance from the operation site, which makes the initial operation more complicated. To overcome the autograft limits, many substitution biomaterials have been proposed. Materials of human and animal origin have the disadvantages of limited supply and potential risk of cross contamination.[5,6]. Consequently, synthetic products were developed.[4]; generally Biphasic calcium phosphate (BCP), an intimate mixture of hydroxyapatite (HA) and ß-tricalcium phosphate (ß-TCP) [5] or pure B-TCP was proposed in dentistry as reference for synthetic materials. However xenograft as BioOss® derived from bovine bone was largely used in dentistry in spite of animal origin material. BCP offers the potential for bone reconstruction since it has a chemical composition close to biologic bone apatites, and has already proven its efficacy as a bone substitute material in many human clinical applications.[6,13]. The concept of HA and β-TCP mixture (BCP) with varying HA/β-TCP, demonstrated the bioactivity of these bioceramics. Subsequently, focussed studies on BCP led to the significant increase in manufacture and use of BCP as bone substitute materials for dental and orthopaedic applications and for matrices for tissue engineering. However scare human clinical studies for bone reconstruction to support further dental implantation have been published to compare synthetic Bioceramics and bone substitute of animal origin.

Fig.1 : 3mm in diameter bone biopsy before titanium implantation

Materials and Methods

The micro macroporous biphasic calcium phosphate (MBCP ®) is an intimate mixture of HA and TCP with a ratio of 60/40. The granules size was 0.5 to 1mm. The total porosity is 70% constituted of 30 % micropores and 70% macropores over 300µm. and BioOss® (no micro and macroporosity) were used in the same Sinus Lift augmentation procedure in humans.

Patients were treated under local anesthesia by para apical and palatin infiltration. Crestal incision, followed by vertical discharge were associated to the displacement of all the total thickness mucosa. The bone window was created by drilling using a diamond bur, then, the Schneider membrane was displaced slightly. Using classical techniques for sinus lift, 1 to 2 cc of 0.5 to 1mm of granules were used. After wetting the granules into sterile water the granules were gently packed under the mucosa taking care of mucosa lesion. Amoxicilline 2g/d were realized during 8 days and Ibuprofène 1200mg/d during 4 days.

Before dental implantation, under local anesthesia biopsies were performed using a cylindrical trocard and irrigation, 3mm in diameter (fig.1) (2 for MBCP, and 1 BioOss®), bone biopsies were harvested. The biopsies were fixed in a formalin solution, dehydrated with graded alcohol and embedded in GMMA for histological analyses. Before sectioning process using diamond saw and a hard tissue microtome, the blocks were analysed with microCT (Skyscann 1072). On thicker sections (100µm), SEM observations using backscattering electron (BSE) combined to Image analysis were used for bone ingrowth and bioceramic resorption evaluation. Light microscopy was performed on 7 µm thick section (Movat's pentachrome staining) and polarized light microscopy on thick section of 100µm without staining.

Results and discussion

In all patients, radiograph revealed newly formed bone with higher density, indicating after 6 to 8 months residual unresorbed grains of bioceramics (MBCP or β-TCP), while for BioOss®, X-Ray was unable to differentiate the material from the natural bone. During drilling, bone density was high without interference with residual granules (fig.2).

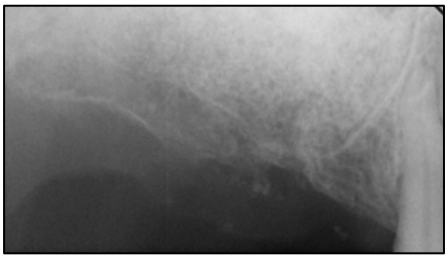

Fig.2 : Sinus Lift augmentation using MBCP, 6 months



Fig.3 : Micro CT MBCP,

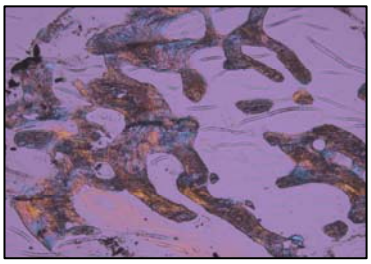

Fig.4 : Polarized microscopy MBCP,

Dental implants have good mechanical stability according classical test performed after the surgery.

Micro CT demonstrates 3D bone ingrowth, and radiodensity changes of the unresorb granules for MBCP (fig. 3). The residual granules look different in density and structure than granules before implantation. This observation confirms the physicochemical modification of the mineral synthetic phases of HA and b-TCP into Biological apatite. Over 30% granules resorption was observed in one patient and over 80% on the second.

In SEM and light microscopy, organized and well mineralized bone ingrowth is observed. in some part of the biopsy total resorption of the MBCP® were observed and replaced by bone trabeculae (fig.4).

This data confirm the resorbability on time of MBCP® and the scaffold effect of the HA content and high osteoconduction property. These two properties involved a balance resorption and bone ingrowth at the expense of the micro macroporous Bioceramics. This achieved an architectured bone regeneration required for physiological bone reconstruction.

For BioOss, no newly formed bone can be observed between the granules (fig. 5). A fibrous tissue as observed between the granules without any osteoid or newly formed bone. No resorption process can be evidenced. (fig. 6).. In human, these results are in contradiction with the biofonctionality of the implanted area in regard to the implant stability. It was necessary to have additional human biopsies, larger representative, to understand why without granules resorption and bone ingrowth at the expense of BioOss®, clinical efficacy was reported by the surgeons during theirs clinical practices.



Fig. 5 : Light microscopy,BioOss,, showing granules without bone ingrowth and resorption process

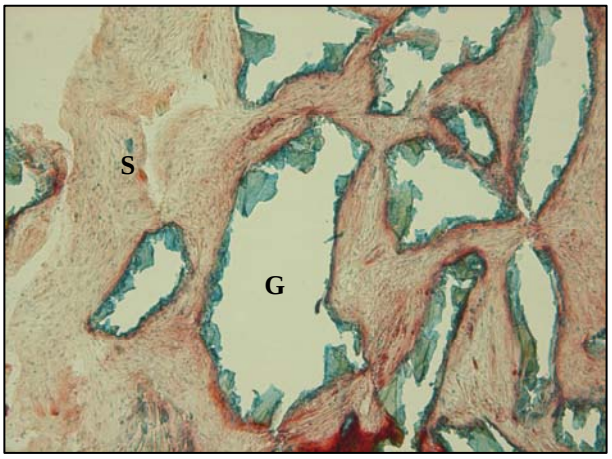

Fi. 6 : Light microscopy,BioOss,, S soft tissue, G granules

Bone ingrowth at the expense of Micro Macroporous Biphasic Calcium Phosphate after human implantation for Sinus Lift Augmentation at 6 and 8 months was confirmed in micro CT, SEM and light microscopy. It is known that pure TCP as RTR® for example have a larger resorption on time, but the architecture of the newly formed bone was different, due to difference in bone ingrowth at the expense of the granules and osteoconduction process. For xenograft like BioOss, no resorption and bone ingrowth was noticed confirmed previous report comparing synthetic calcium phosphate and such bone substitutes [10]

Micro CT calculation indicates that during the 6 initial months, 53% of MBCP granules were resorbed and 22% of newly formed bone was intimately associated to the surface of residual granules and between them.

SEM and polarized light microscopy revealed a decrease in the density of the granules. This will be due to physico chemical changes of the BCP crystals, a classical process previously described of dissolution of the BCP and precipitation of biological apatite into the micropores [11].Light microscopy shows osteoid and bone formation between the granules and closely associated to the surface. Hematopoietic cells and new vascularization demonstrates the high osteogenic property and the vitality of the newly formed bone (fig 4).

Polarized light microscopy indicates that newly formed bone was constituted of lamellar bone surrounding the particles and in some part, trabeculae of woven bone. Bone remodelling appears clearly in some biopsies without regular distribution. This will be due to non bearing area before dental implantation.

Conclusion

It appears that the bone filling of sinus realized with micro macroporous biphasic calcium phosphate granules MBCP, after 6 to 8 months have enough bone ingrowth to support dental implant. Histology and micro CT performed on the biopsy before the dental implantation revealed high bone ingrowth and the bone architecture suitable for mechanical stability during the osteointegration. For BioOss® in spite of good clinical efficacy, non resorption and bone ingrowth were observed after 6 months of implantation. Additional human biopsies were in progress to be more representative of the differences in bone regeneration observed during sinus lift augmentation using different types of bone substitutes. .

Aknowledgement: We thank Françoise Moreau and Sophie Sourice for their technical assistance and Monika Gottlob for text revision. This work was supported by ERT 1051 from Nantes University

1 Barboza E.P., Int. J., Periodontics Restorative Dent. 19 (1999) 601

2 Al Ruhaimi K.A., Int. J. Oral Maxillofac. Implants 16 (2001) 105

3 Vastel L., Lemercier V., Kerboull L., Kerboull M., Rev Chir. Orthop. Reparatrice Appar. Mot. 85 (1999) 164

4 Legeros R., Parsons J.R., Daculsi G., Driessens F., Lee D., Liu S.T., Metsger S., Peterson D., Walker M: Bioceramics: Material characteristics Versus in vivo behavior, Ann. N.Y. Acad. Sci. 523 (1988), , 268-271.

5 Daculsi G, Laboux O, Malard O, Weiss P. J Mater Sci Mater Med. 2003 Mar;14(3):195-200.

6 Daculsi G., Passuti N., Martin S., Deudon C., LeGeros RZ.(1990).. J. Biomed. Mater. Res., 1990, 24, 379-396

7 Pascal-Moussellard H., Catonné Y., R. Robert R., Daculsi G., (2007). Proceedings ESB 20, Nantes France

8 Gouin, F., Delecrin, J., Passuti, N., Touchais, S., Poirier, P, Bainvel, J.V. (1995). Rev Chir Orthop 81:59-65

9 Ransford A.O., Morley T., Edgar M.A., Webb P., Passuti N., Chopin D., Morin C., Michel F., Garin C., Pries D. (1998). " J Bone Joint Surg Br 80(1): 13-18.

10 Cavagna, R., Daculsi, G., Bouler, J-M., (1999).. Long term Effects Med Impl 9 : 403-412 23

11 Nery E.B., Eslami A., Van S.R., J. Periodontol. 61 (1990) 166

12 Piatelli A., Scarano A., Mangano C., Biomaterials 17 (1996) 1767

13 Block M.S., Kent J.N., J. Oral Maxillofac. Surg. 44 (1986) 89

14 Daculsi, G., Corre, P., Malard, O., Legeros, R., Goyenvalle, E., Key Engineering Materials 2006, 309-311: 1379-1382

15 Daculsi G., LeGeros RZ, Nery E., Lynch K , Kerebel B. (1989). J Biomed Mat Res 23: 883-894