The Biology of 4-Week Implant Placement

Since Dr. Brånemark discovered integration of bone to titanium, the factors that guide successful implant integration have not changed. Good bone, good implant torque, and an optimized titanium surface are still the factors that are considered necessary for successful implant integration and long-term function. These factors have also been applied to delayed implant placement after tooth extraction. Delayed implant placement in extraction sites is based on the same criteria requiring mature mineralized bone that can provide adequate torque for successful implant integration. When left to heal on its own, bone heals slower and never normally. Gingiva, on the other hand, heals at a much faster rate. Gingiva and bone are intimately interconnected and require each other for optimum healing. There is crosstalk between all adjacent tissues, and for optimum regeneration, all tissues must heal synergistically.

There is new science developing regarding the tissue interactions during growth and repair. Bone and muscle provide molecular cross communications with each other during growth and repair that is required for optimal tissue formation and regeneration. If one tissue is deficient, it will compromise the healing of the adjacent tissue, resulting in an inferior clinical outcome.

Bone and gingiva are no different. If we can reestablish the synergy between gingival and alveolar healing with both tissues healing and maturing at the same rate, a paradigm shift in implant placement is possible. With the application of new bone graft technology, it is now possible to match the healing rate of gingiva and bone to bring back the synergy between the two tissues. SteinerBio bone graft technology reestablishes bone regeneration potential and marries the rate of bone growth to the remodeling rate of the gingiva, allowing for implant integration during gingiva/alveolar healing.

With no graft or with traditional graft materials during the first month, the gingiva is actively healing, yet no bone is formed during this period and the collaboration between gingiva and bone is lost. With no graft or with traditional graft materials, a blood clot must form followed by granulation tissue, then collagen plug, and ultimately bone begins to form after on month. However, due to SteinerBio osteogenic materials, this one-month lag in bone formation is skipped. After 4 weeks, the socket is filled with proliferating osteoblasts and mineralized bone, restoring the healing synergy between gingival and alveolar tissues.

CASE 1

The following case outlines the process of accelerating bone formation to produce complete mineralization of the extraction socket in 4 weeks.

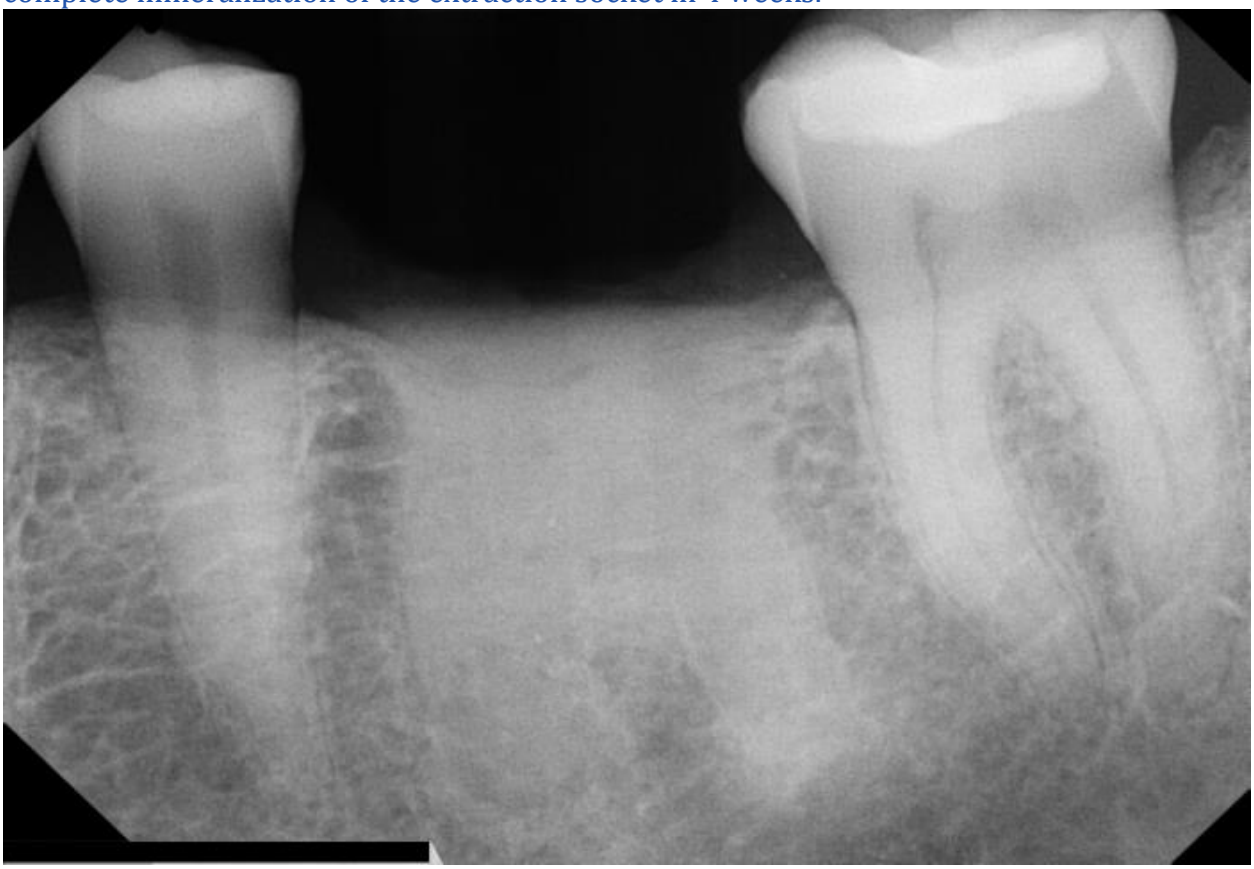

This radiograph shows **Socket Graft™** in place the day of extraction, covered by a Teflon (d-PTFE) membrane.

This radiograph was taken at two weeks with normal adult radiation exposure. Socket Graft™ is a dual phase calcium phosphate biocement. The first phase is designed to wash out during the first week to provide porosity for migrating osteoblasts. In this radiograph, the roots of the sockets are filled with bone. The coronal portion of the socket shows the first phase of the bone graft has washed out with no bone formation at this time point.

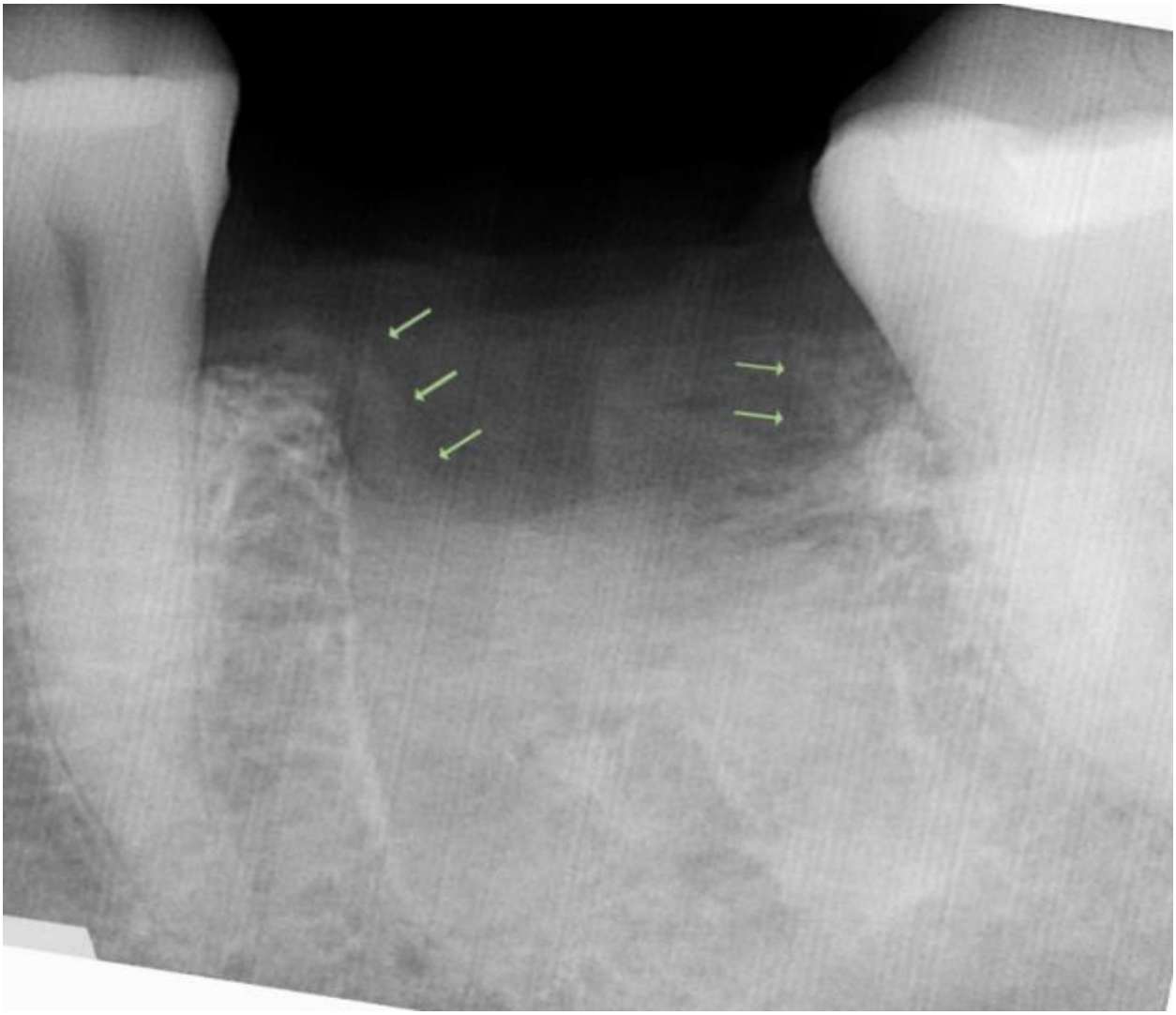

This radiograph is of the same two-week time period as the previous radiograph, but using a pedo setting to reduce radiation exposure, which allows for better viewing of incipient bone formation and residual graft material.

The radiograph shows the residual graft material in the coronal portion of the socket but also identifies incipient bone formation along the mesial and distal wall of the socket. In socket healing, the majority of bone formation is from the apical portion of the socket. This is due to the body of the mandible containing a far greater amount of regenerative cells which fill the roots first and then grow toward the crest. In this case, however, there is a significant amount of interseptal (interdental) cancellous bone. The width of the interseptal bone plays a crucial role in determining the rate of bone formation at the crest. In instances

where there is narrow interseptal bone there is very little cancellous bone and therefore very few regenerative cells. In cases of minimal interseptal bone, there is often only cortical bone on the buccal and lingual with no regenerative cells, which result in slow mineralization of the socket crest and greater resorption. However, in this case there is a significant width of mesial and distal cancellous bone that contributes to crestal bone formation which can be seen by the arrows.

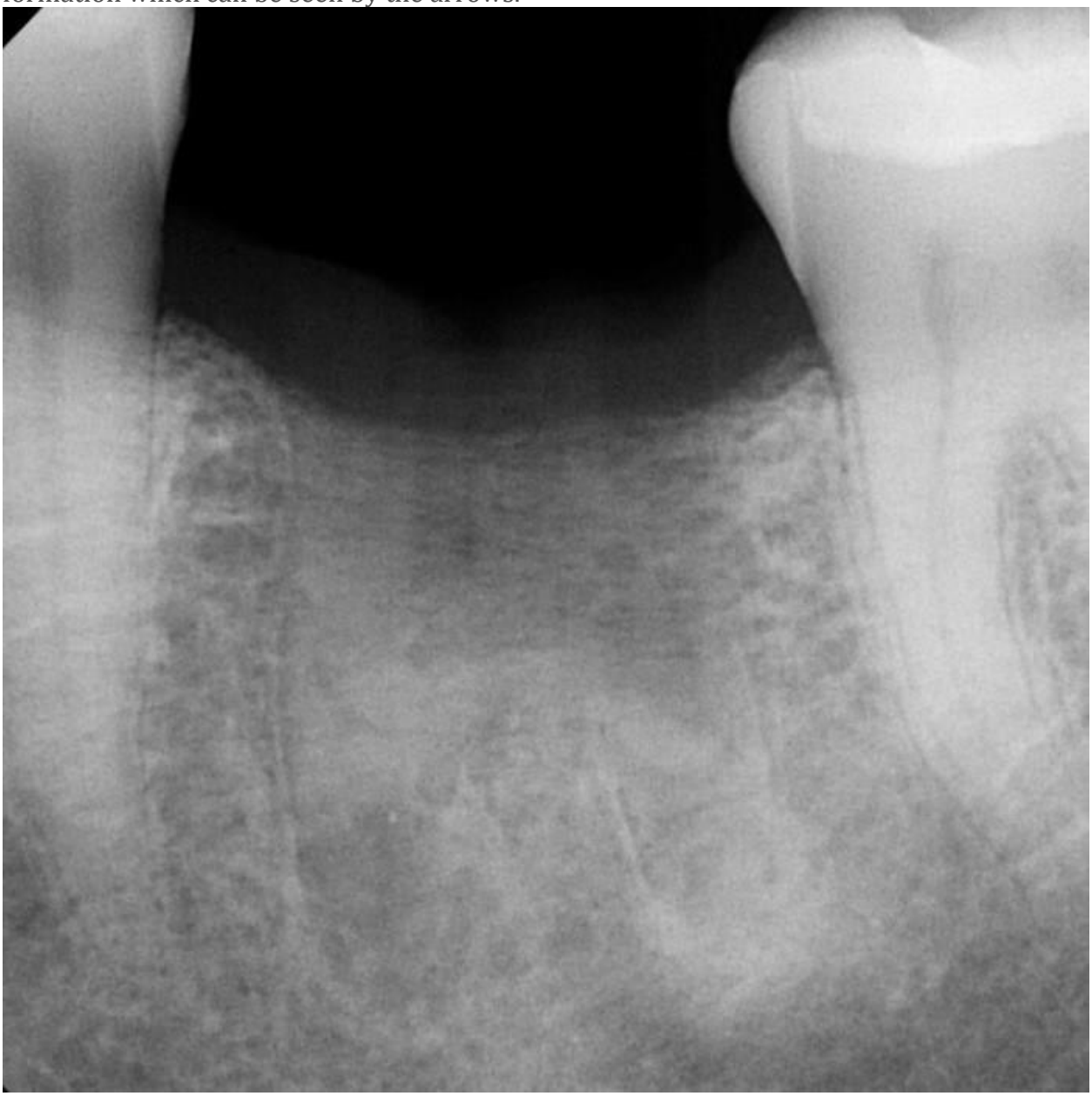

This is the 4-week radiograph with normal adult radiation exposure. The socket is now filled with mineralized tissue. At this point, the socket is filled with the maximum number

of osteoblasts and is theoretically the most ideal time for implant placement for maximum implant integration.

However, it is difficult to surgically delineate the gingiva from the bone at this point. Waiting another month will double the percent of mineralized tissue and produce a crest that can be surgically identified. Most dentists think that high torque and hard bone is the best for implant integration, but this is completely wrong. The mineralized portion of bone contains no osteoblasts and therefore provides for no implant integration. Osteoblasts only reside in the soft tissue stroma and provide no resistance to torque. The more osteoblasts the better the integration.

When using bone graft materials that produces normal, healthy, vital bone, early implant placement ensures a high level of implant integration. Because of an ideal anatomy with good mesial and distal cancellous bone, all socket walls present and a rapidly resorbed graft material that stimulates osteogenesis this patient is ready for implant placement 2 months after extraction.

At the 4 week time period, if the site was not grafted, the socket would be filled with dense collagen and very little bone. When a tooth is extracted and not grafted, it goes through a cycle of clot, granulation tissue, and then collagen before any bone is formed, which takes a month. With Socket Graft™, the clot- granulation tissue-collagen plug is skipped and bone formation begins immediately. With Socket Graft™, bone formation is accelerated by SL Factor and elemental calcium phosphate. Calcium phosphate in its elemental state is known to stimulate bone formation and Socket Graft™ is the only bone graft on the market that contains calcium phosphate in elemental form which contributes to the bone formation shown on these radiographs. Ceramic bone grafts that contain calcium phosphate do not stimulate bone formation because the particles must be encased in bone before osteoclasts can release the calcium phosphate during resorption and therefore it is too late in the process to stimulate bone formation.

Any particulate synthetic bone graft material will proceed through the same process of clot, granulation tissue, and collagen plug during the first month, followed by

osteoconduction—just like a socket without graft. The presence of biocompatible but biologically inert granules produces the same amount of bone at the same rate but it will maintain volume due to the presence of the granules.

When using cadaver bone grafts, there is no way to know if bone has formed radiographically. The process of bone formation for cadaver bone grafts is different than normal bone formation as it takes place on the graft particles and not from the surrounding bone. At 4 weeks, no bone formation will have occurred in a socket grafted with a cadaver bone graft.

CASE 2

Displays significant recession and is planed for extraction due to endodontic disease. #9 was extracted and grafted with Socket Graft™ and covered with a Teflon membrane.

The membrane was removed after 4 weeks and the implant was placed with healing abutment. Because the volume of the gingiva was maintained, the healing abutment rests at the level of the gingiva. The presence of the healing abutment maintains the volume of the gingiva.

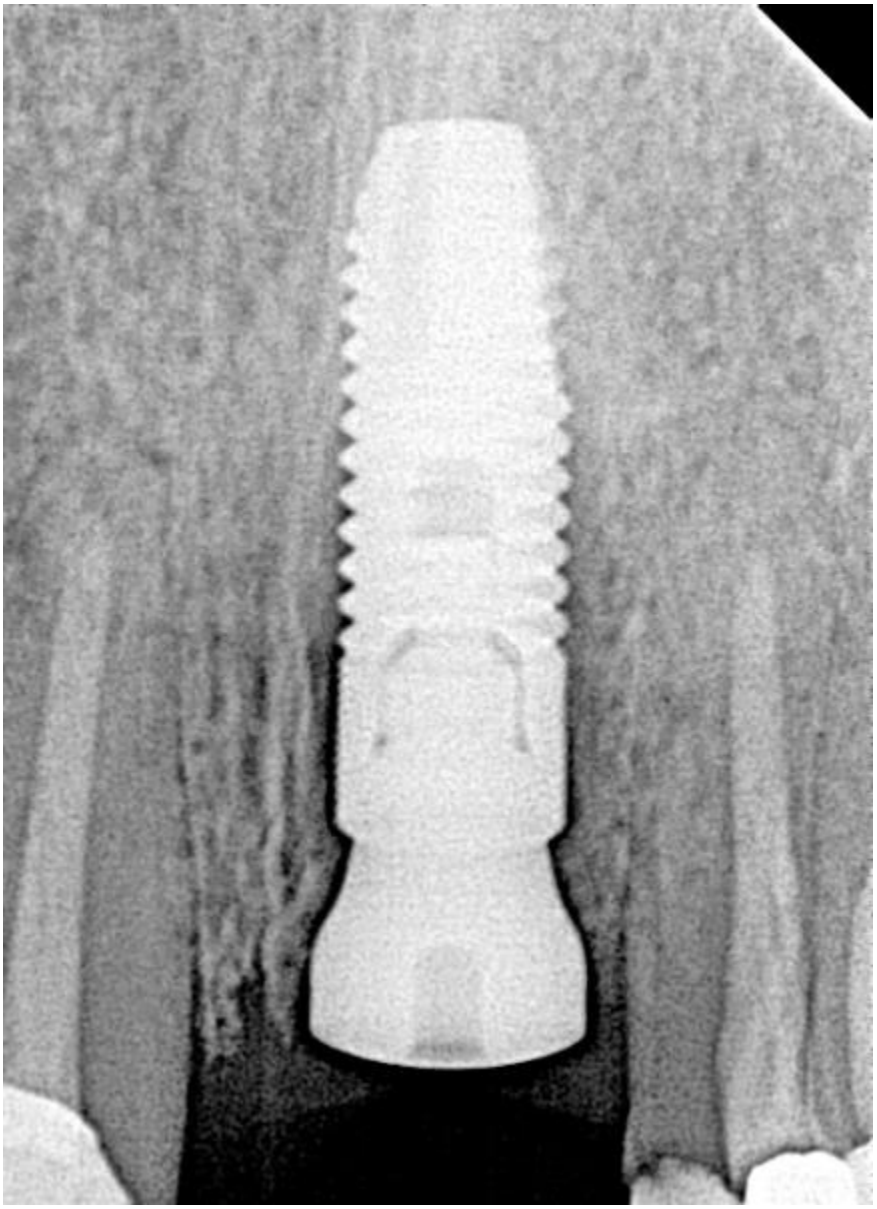

One month after implant placement. The implant is integrated and the alveolar bone has grown around the healing abutment. The patient is referred for impression to be taken 6 weeks after implant placement.

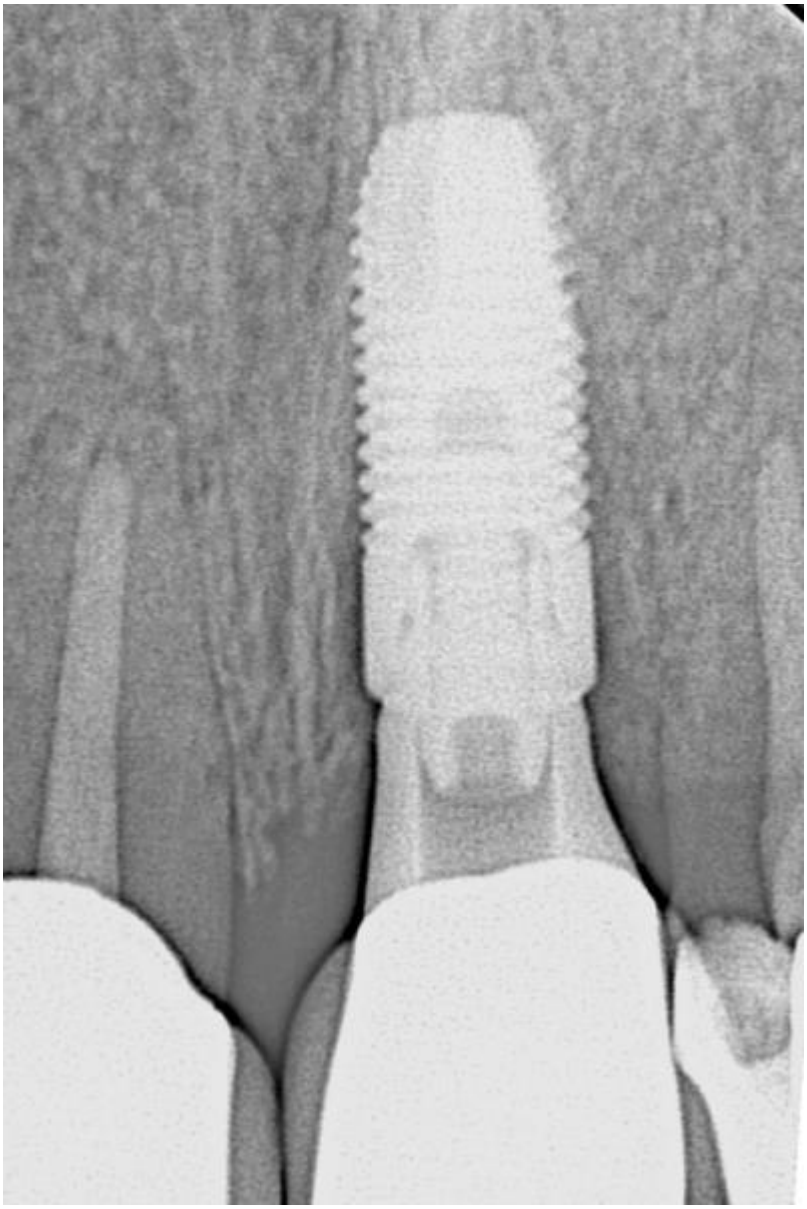

Final restoration in place.

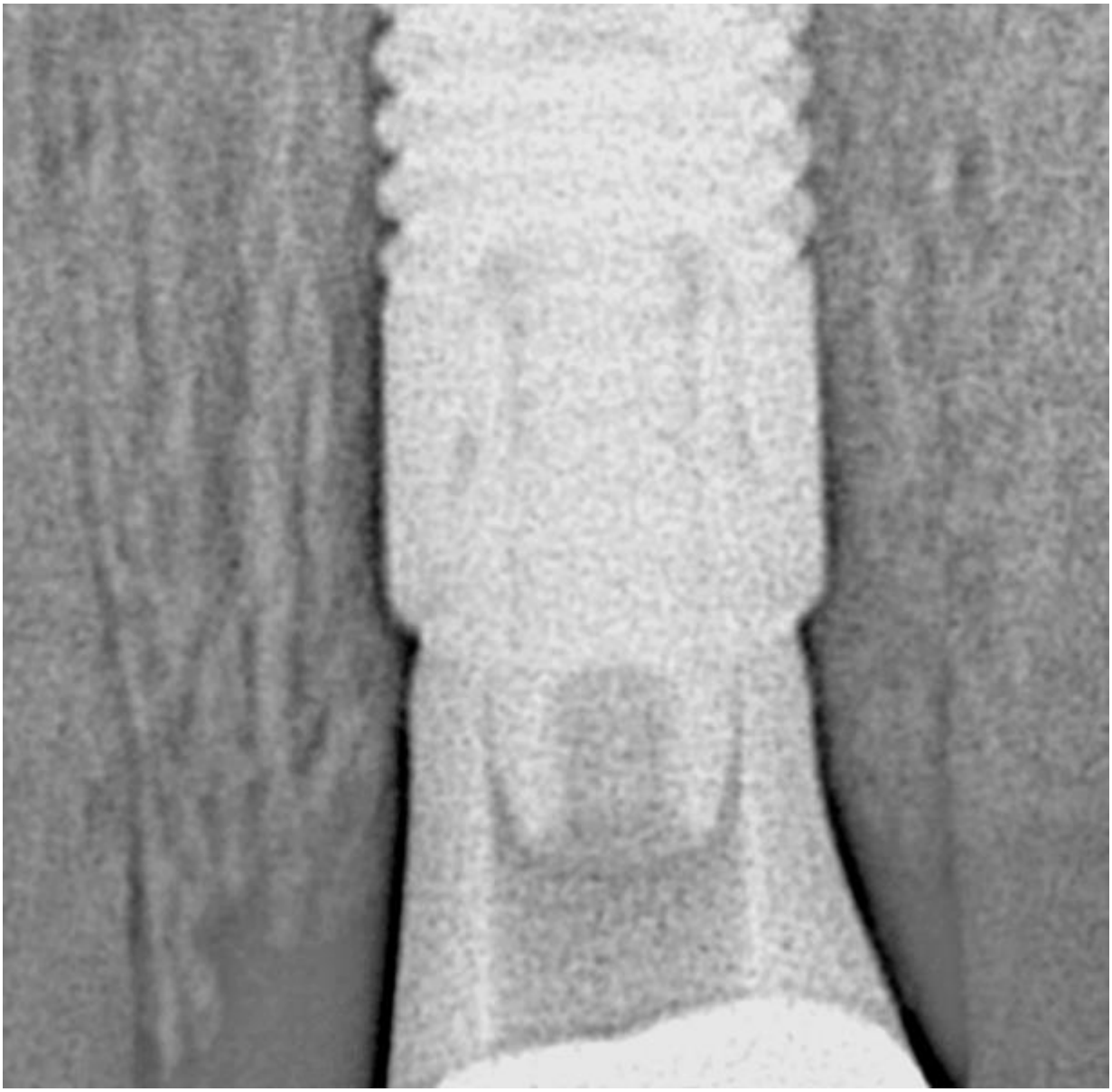

Integration to the implant has occurred and bone has grown around the healing abutment.

The gingival margin has improved and the interdental papilla has been maintained.

CASE 3

#12 was extracted and grafted with Socket Graft™.

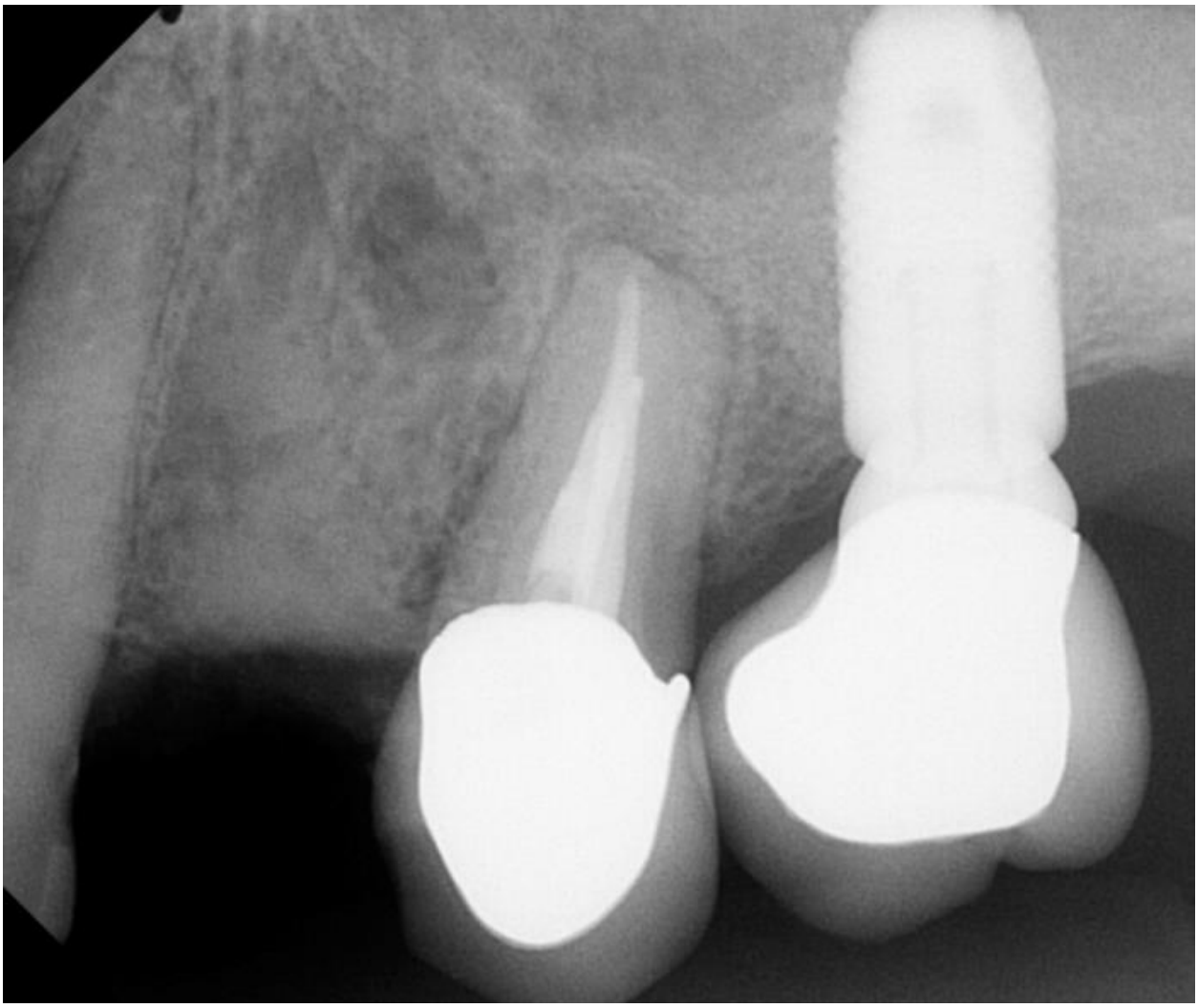

Bone graft in place.

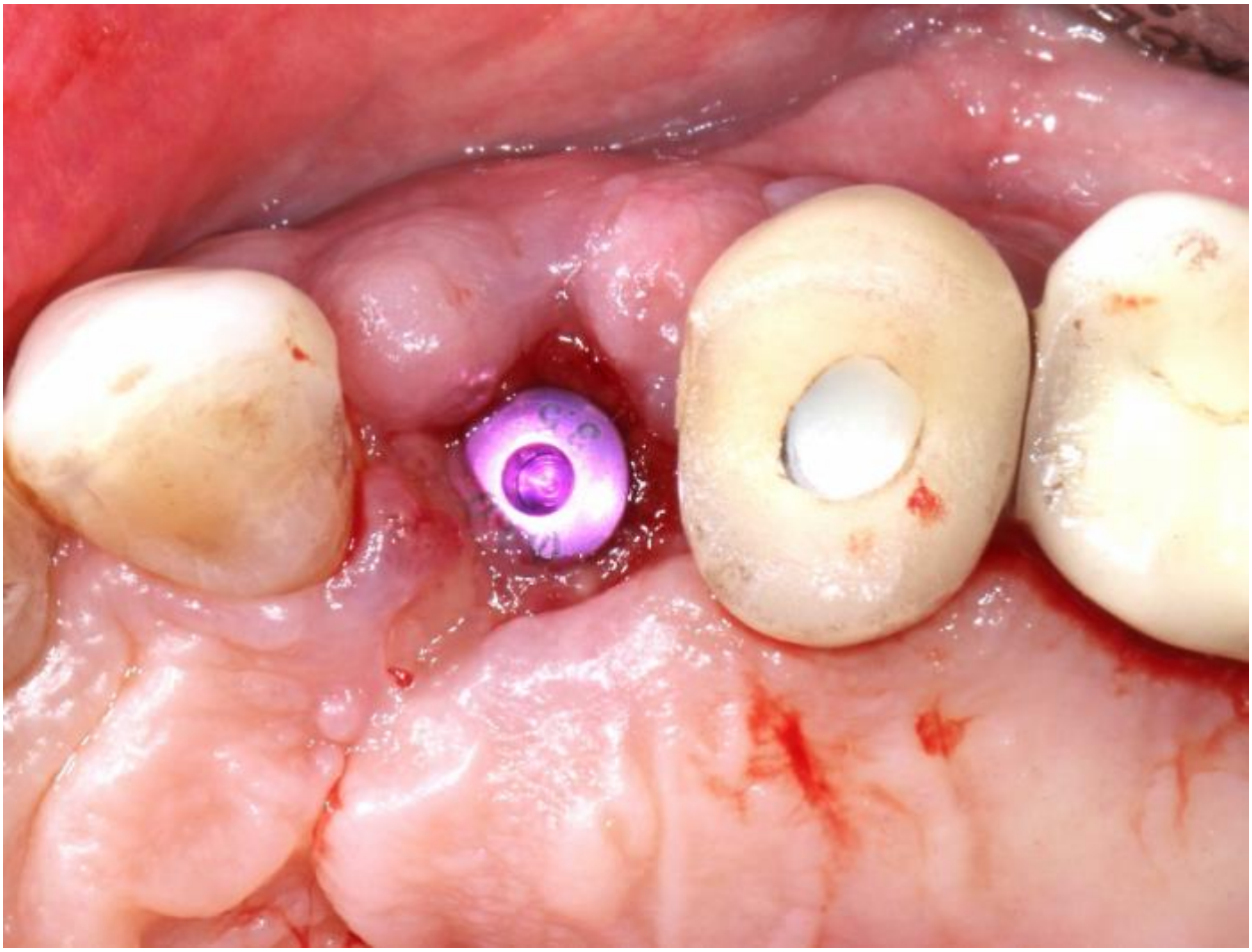

4 weeks after extraction and grafting, the membrane is removed and the implant is placed without incisions or flaps. Implant integration was checked after 4 weeks and the patient was referred for impression to be taken 6 weeks after implant placement.

The final restoration in place. The molar was previously placed at the time of sinus augmentation.

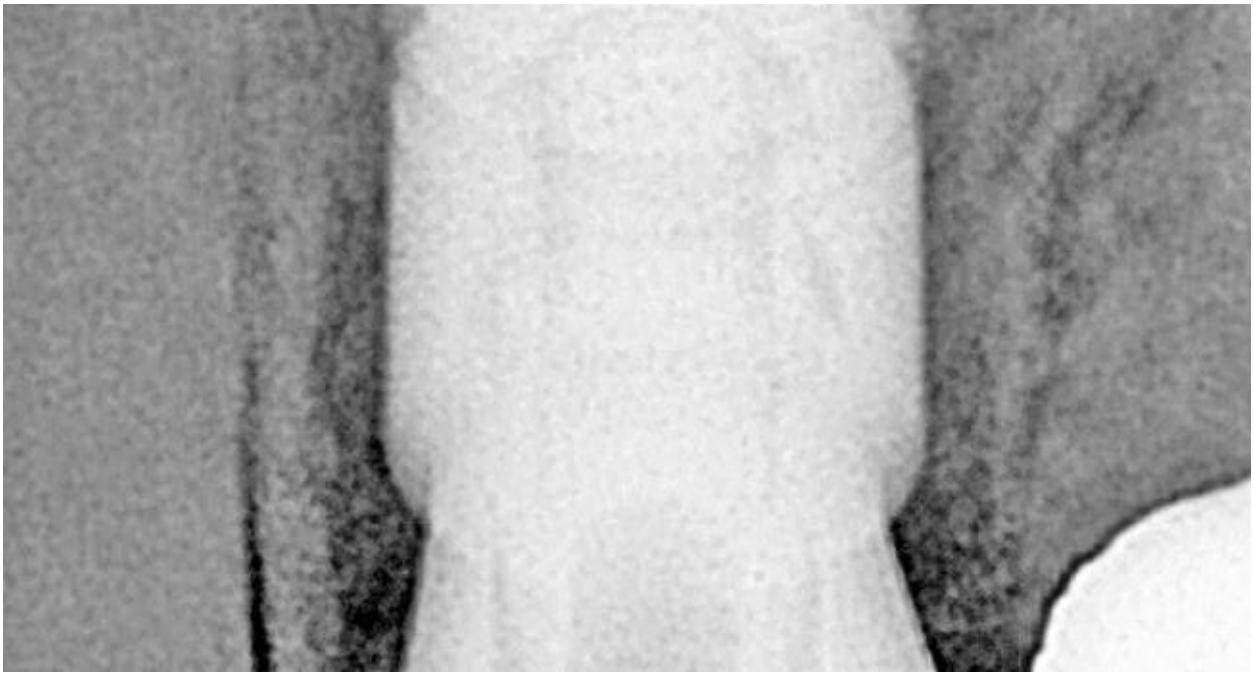

Bone has formed over the implant collar and along the healing abutment.

The final photograph shows a regenerated gingival margin with some papilla regeneration adjacent to teeth with significant recession.

The buccal bone and gingival tissue has been maintained and is still remodeling.

CASE 4

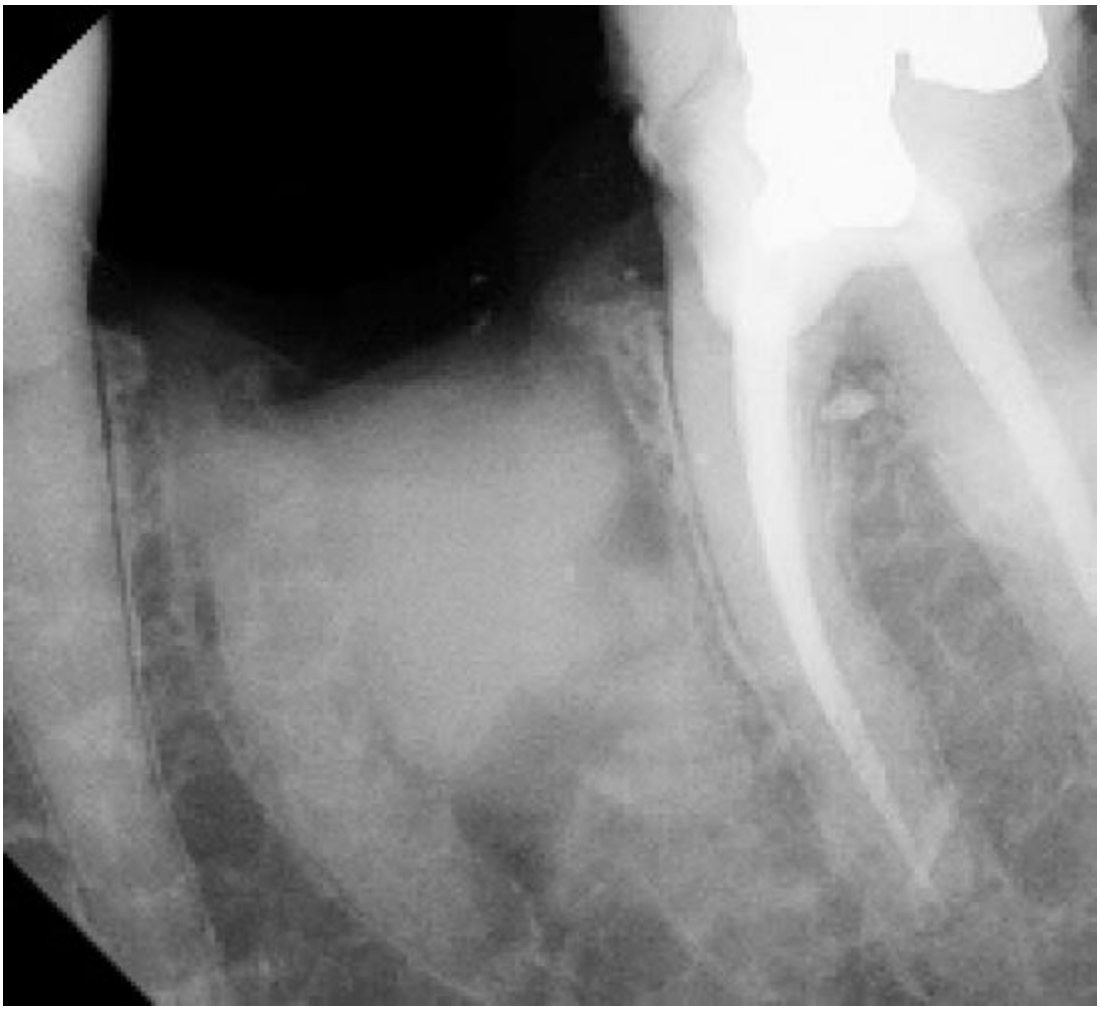

Day of extraction and grafting and grafting with Socket Graft™.

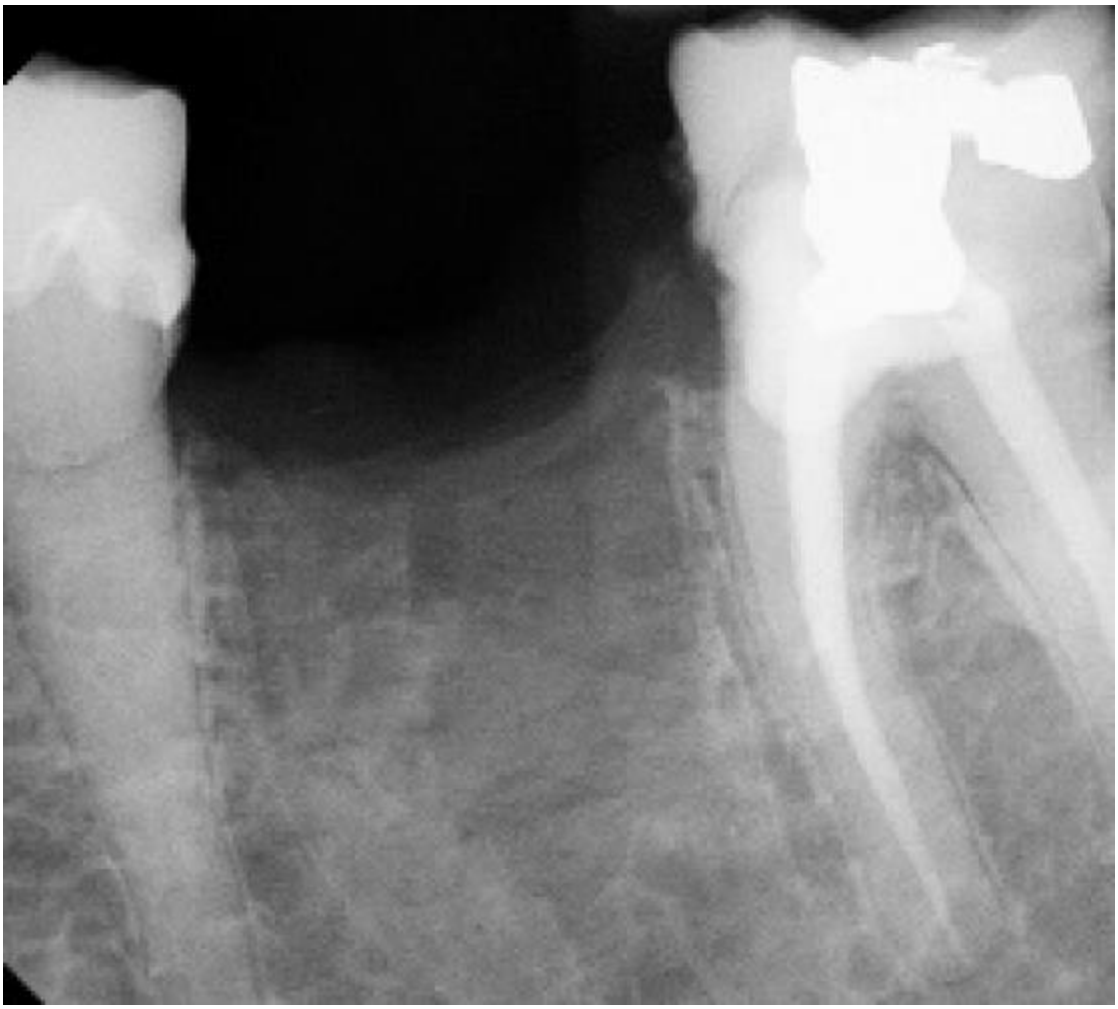

4 weeks after extraction.

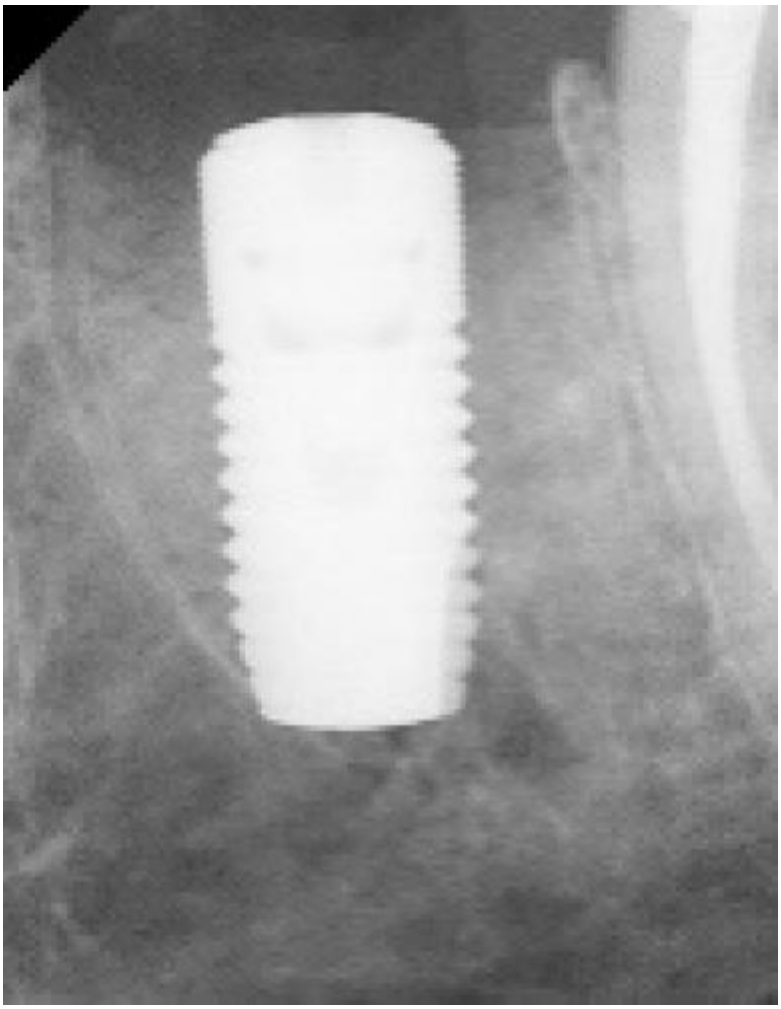

Implant placement 4 weeks after extraction.

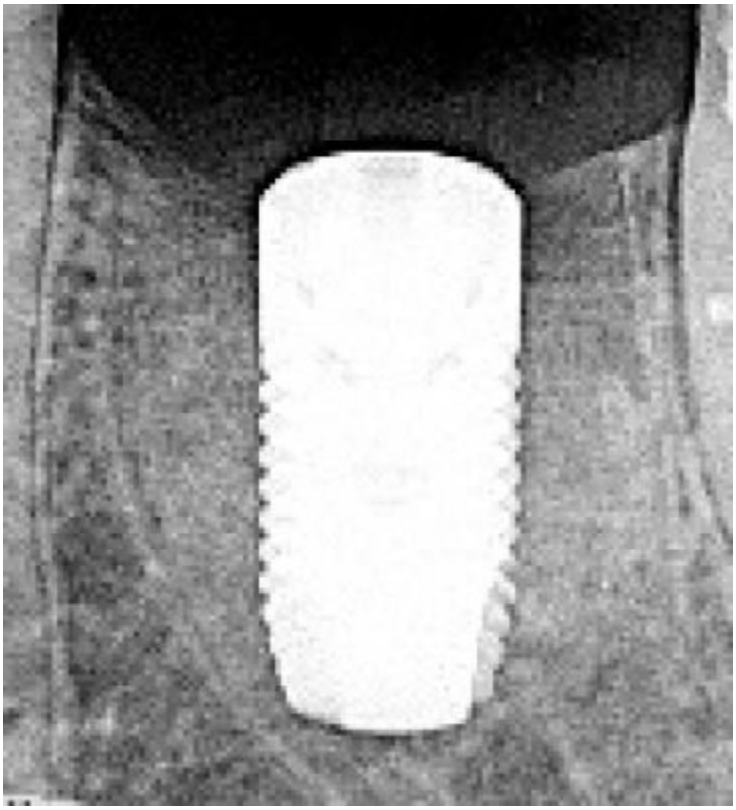

Implant 8 weeks after extraction and 4 weeks after implant placement.

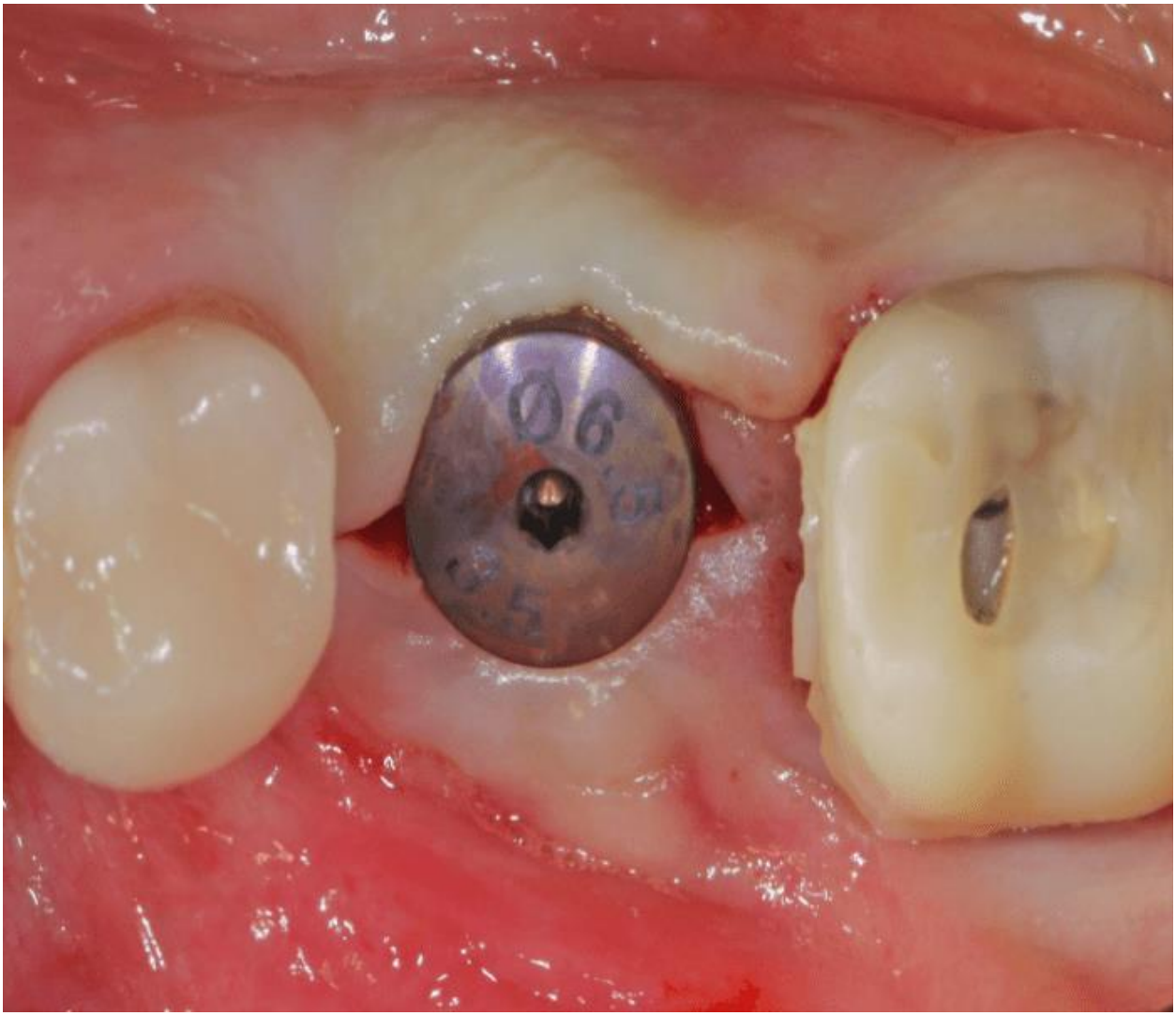

Day of healing abutment placement (4 weeks after implant placement and 8 weeks after extraction). The implant is integrated and the gingiva has maintained its form and volume. The implant is scheduled for impressions 6 weeks after implant placement.

Gingival margins and papilla are maintained, however, gingival inflammation is noted in the mesial buccal gingiva.

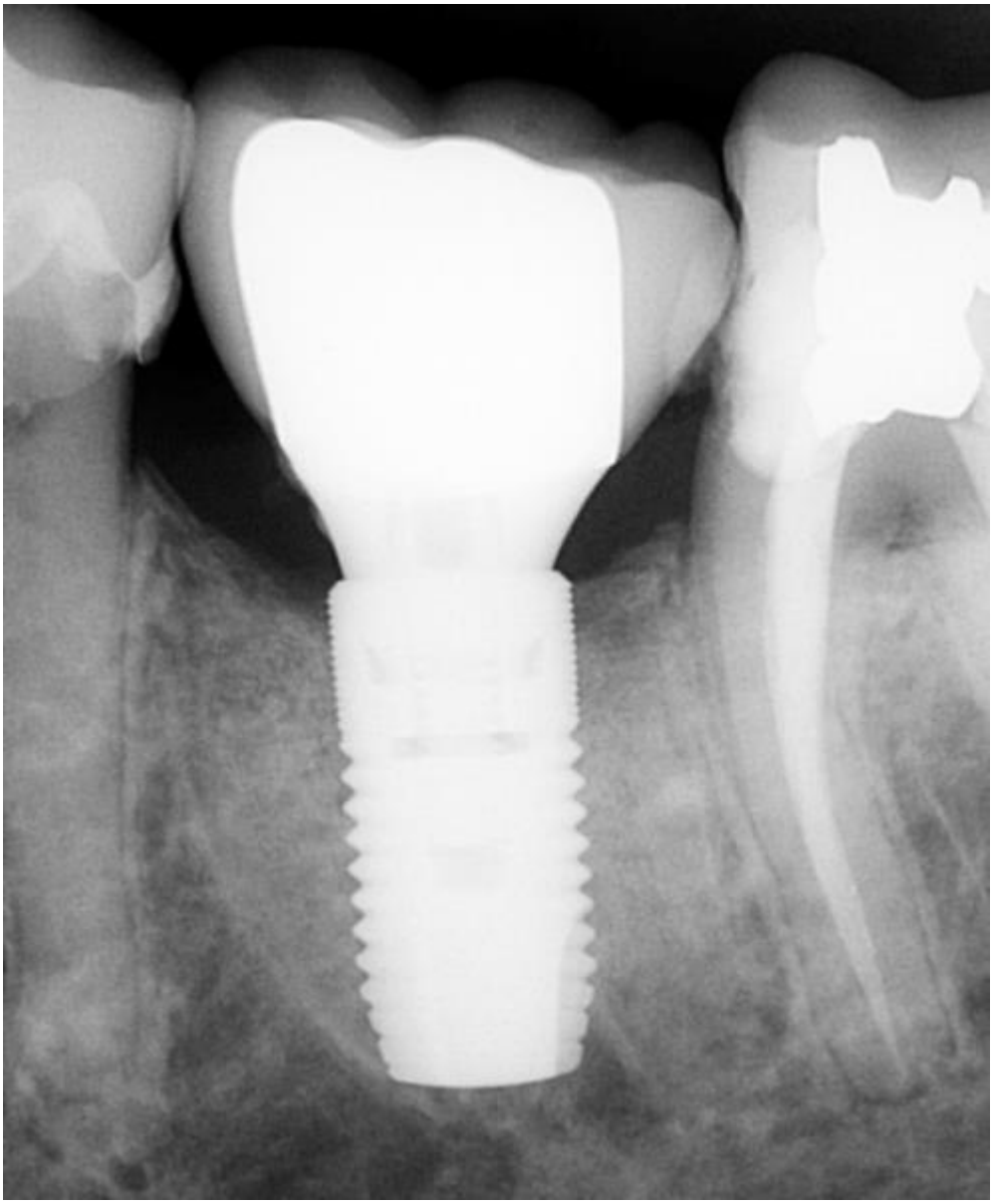

The distal bone has maintained its proper location at the collar of the implant, however, there is a radiolucency at the mesial gingival margin.

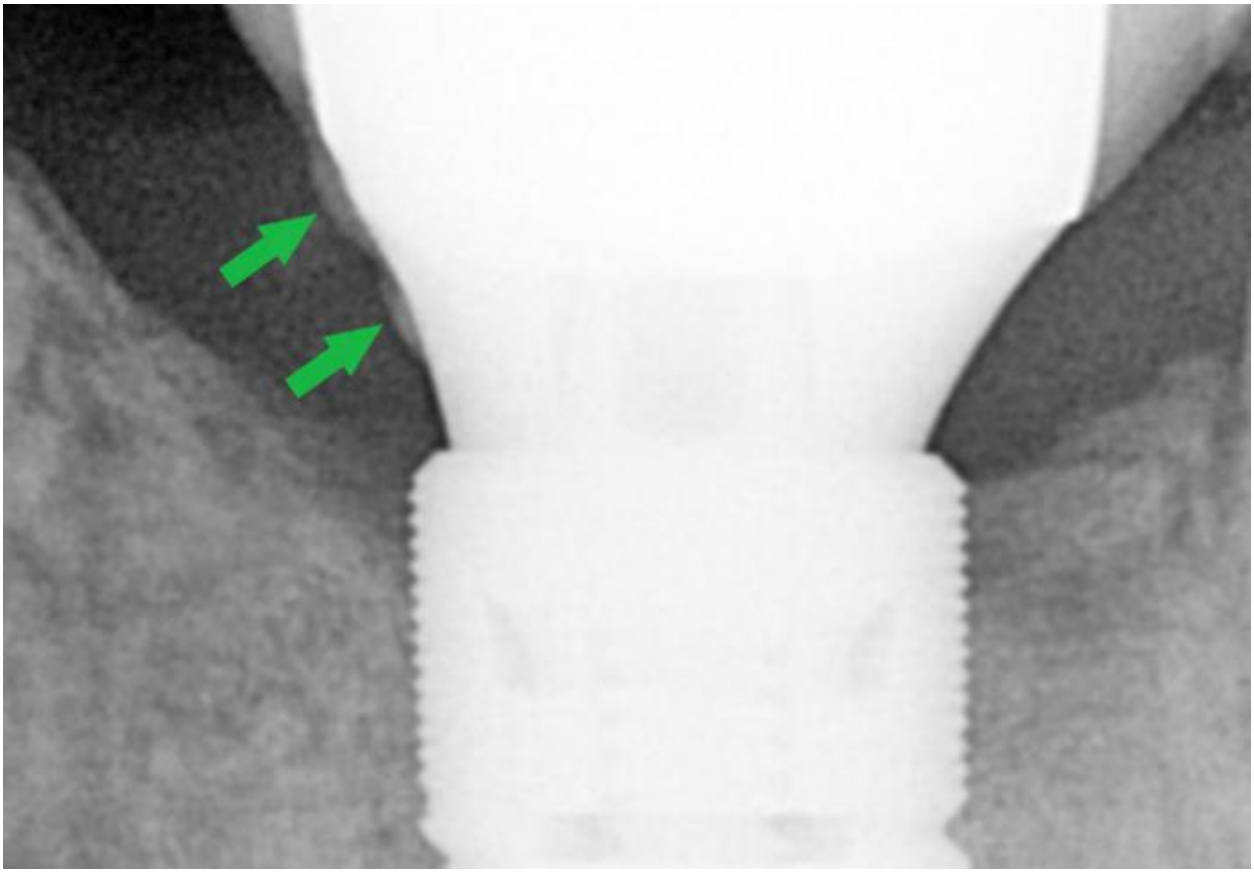

Closer inspection reveals extensive cement on the mesial surface of the crown adjacent to the radiolucency.

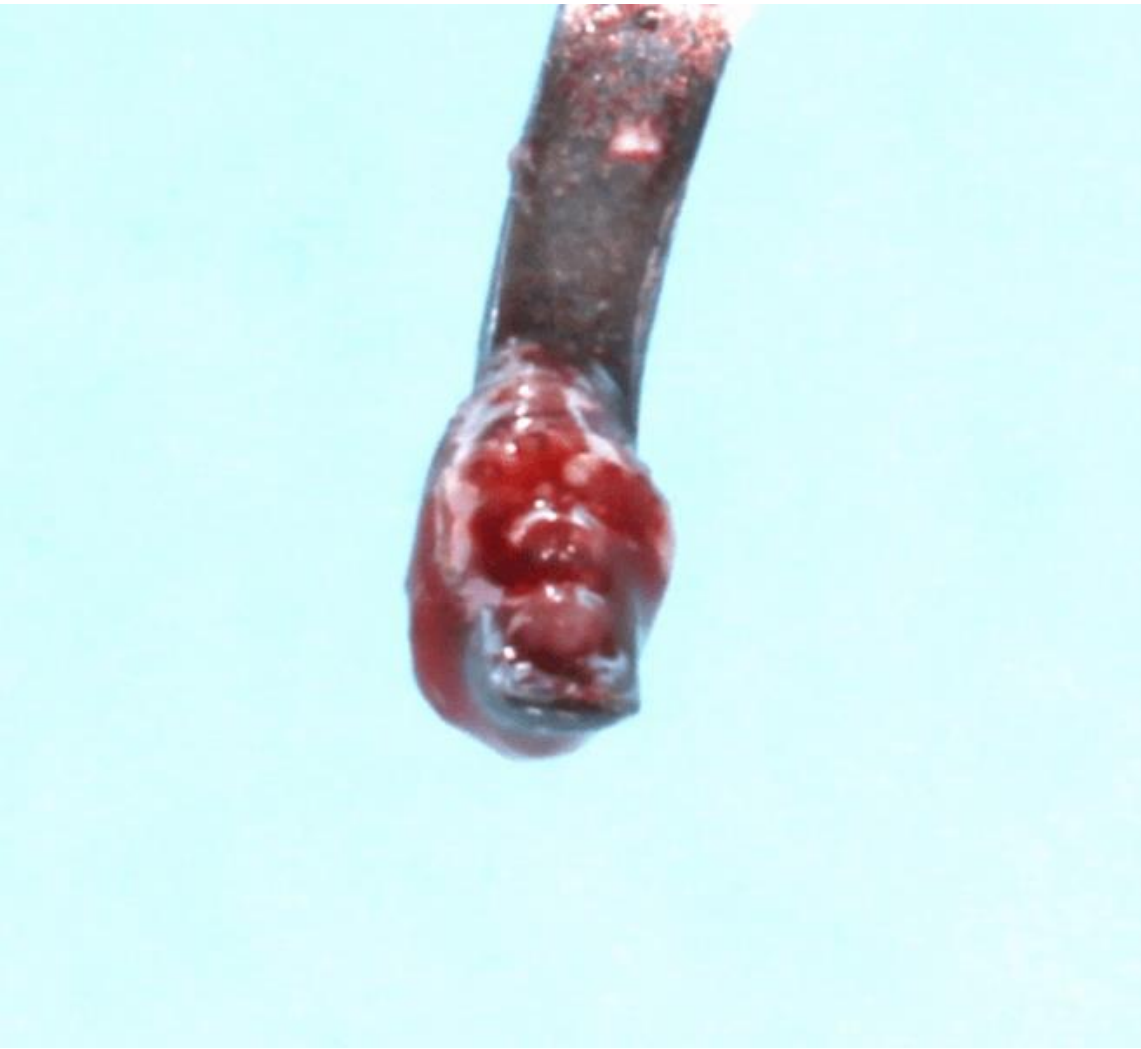

Removal of the cement will resolve the inflammation and hopefully allow the radiolucency to remineralizes.

What are the benefits to you and your patient of this paradigm shift in implant placement?

- Only one surgical intervention rather than two
- Implant placed without incisions, flaps, or sutures
- Only one healing phase rather than two
- Significant reduction in chair time
- Significant reduction in skill and training for implant placement
- Reduction in pain and morbidity for the patient
- Improved gingival esthetics
- 50% reduction in time between extraction and restoration

SteinerBio osteogenic bone grafts are unique in that during a 4- to 6-week time period, the socket contains millions of proliferating osteoblasts producing mineralization. This is the optimal time for your implant to be introduced into the regenerating socket for maximizing bone to implant integration. As the gingiva and the alveolus are simultaneously healing and regenerating, the implant integrates in a shorter time span. With this paradigm shift, the implant integrates as the tissues heal around it. Typically, a non-resorbable membrane is removed and the implant is placed in the exposed tissue without incisions, flaps, or sutures. Membrane removal and implant placement is now a 30-minute appointment. After you have completed this 30-minute procedure on your patient and tell them their implant has been placed and the procedure is complete, you will get a startled look wondering how it could have been so quick and simple. Schedule the patient in a month to check integration and 6 weeks for impressions, with the final restoration being placed within 3 months of extraction.

So, what makes this possible?

Every element in our products is scientifically studied, researched in our animal vivarium, tested under the most demanding conditions, and cleared by the FDA. We are the only bone graft in the world the FDA allows to claim that our products stimulate osteogenesis. SteinerBio has the only bone grafts on the market that contain a drug that changes the physiology of a bone's osteoblasts to stimulate osteogenesis. SL Factor™ enters through the membrane of the osteoblasts then enters the nucleus and results in the following metabolic activities:

- SL Factor™ is absorbed by the osteoblasts
- SL factor activates over 300 genes that stimulate the process of bone formation
- BMP2 and Runx2 production increases two-fold and reduces osteoclast formation by inhibiting the production of RANK ligand
- Osteocalcin accumulation is enhanced in the extracellular matrix resulting in excellent mineralization
- While stored in the osteoblast, SL Factor™ continues to stimulate bone growth after the synthetic matrix has been resorbed
- Adipogenesis, osteoclastogenesis, and ODF/RANK ligand expression is inhibited
- Inflammation is reduced by inhibiting prostaglandin synthesis

SL Factor Absorption

This human histology illustrates what occurs when our graft material is placed in bone. The material becomes hydrated by extracellular fluid and operates as a growth medium. Our patented compound, SL Factor, exists in vacuoles within the material, scattered around the matrix. Osteoblasts migrate from the surrounding bone into the graft material. As they migrate throughout the material absorbing SL Factor, the osteoblasts organize into functional, mineralized bone.

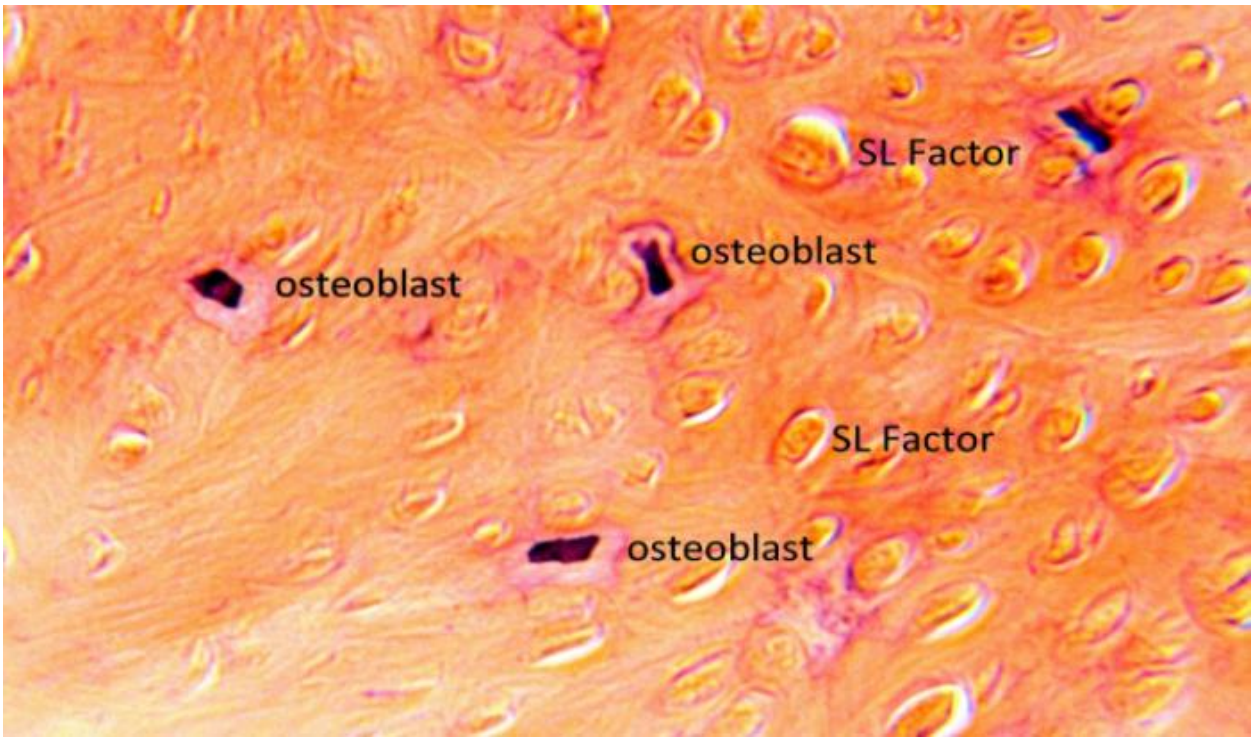

Stimulation and Proliferation of Osteoblasts

This is a histologic section of a site grafted with Socket Graft™. Osteoblasts typically only form on the surface of areas that are mineralizing. However, this image shows an extraordinarily high concentration of osteoblast cells in the middle of soft tissue, illustrating a high level of osteoblast proliferation.

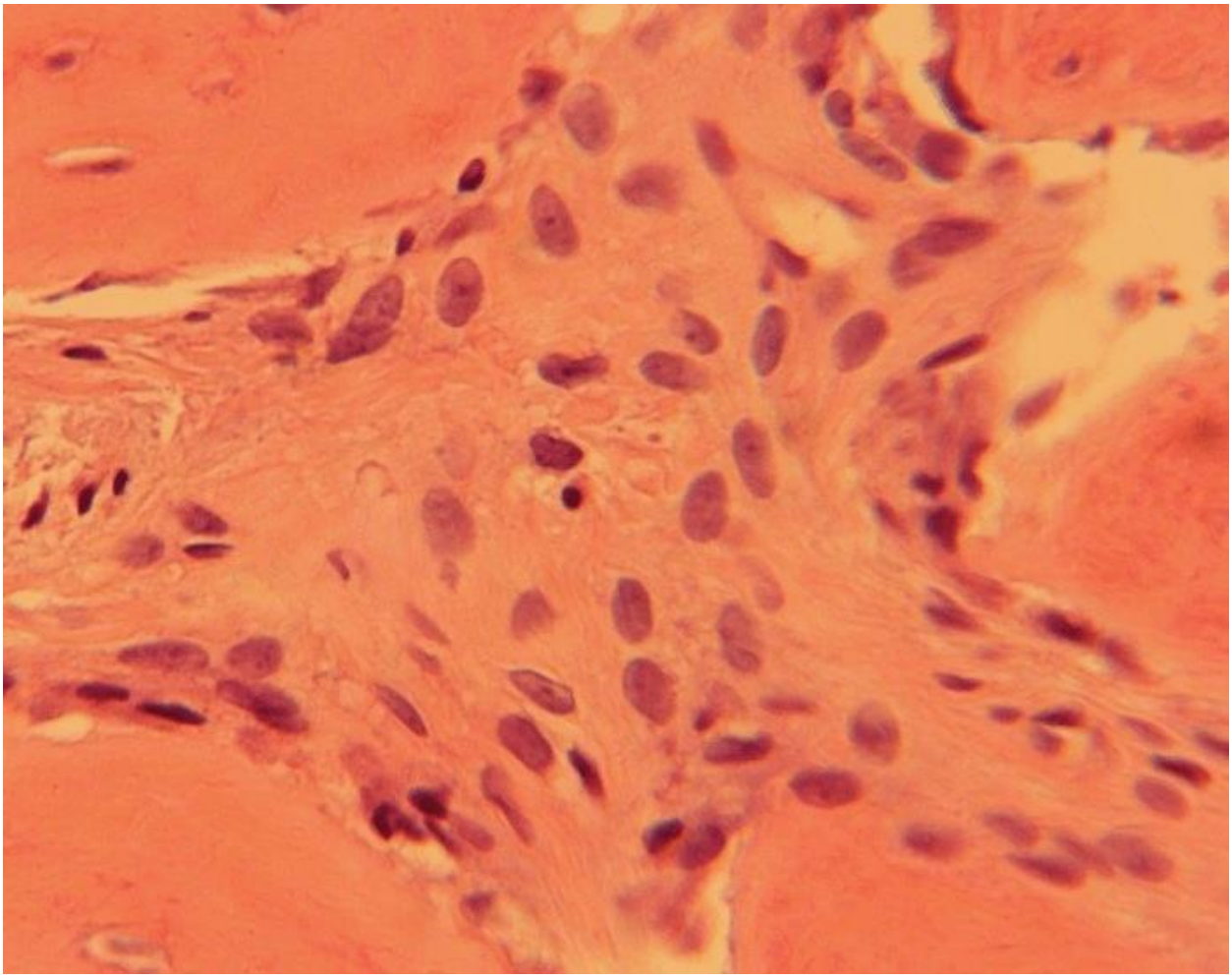

6 Weeks, High Power

Production of mineralized bone is identified by the darker colored material. A thick layer of osteoid is present, which has been secreted by the osteoblasts. The soft tissue that surrounds the mineralized tissue is devoid of any inflammatory infiltrate. What you see are very highly stimulated osteoblasts producing mineralized tissue. The graft material has been rapidly resorbed at 6 weeks. When your implant is in this rapidly mineralizing tissue, excellent integration is assured.

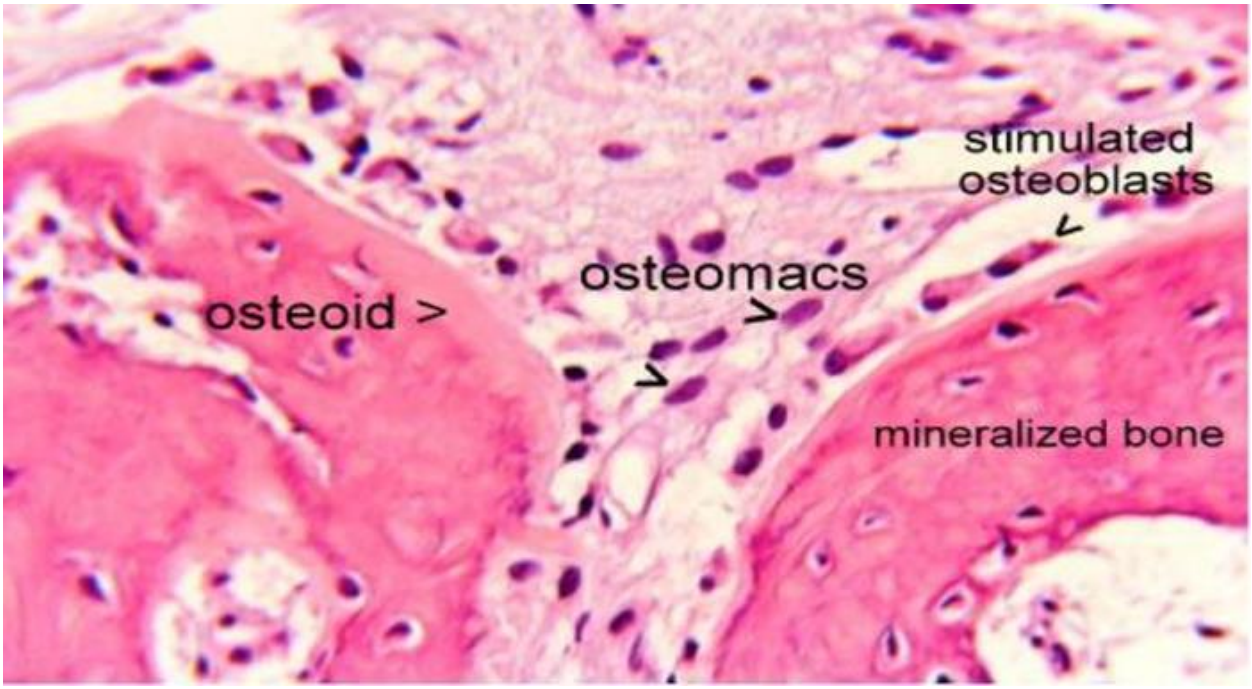

When your patients are told that they can avoid flap surgery if the implant is placed when the membrane is removed and their time to restoration is cut in half, you will not only get your patient's eager acceptance, but you will also acquire their friends and relatives. To learn more about early implant placement, please contact us.