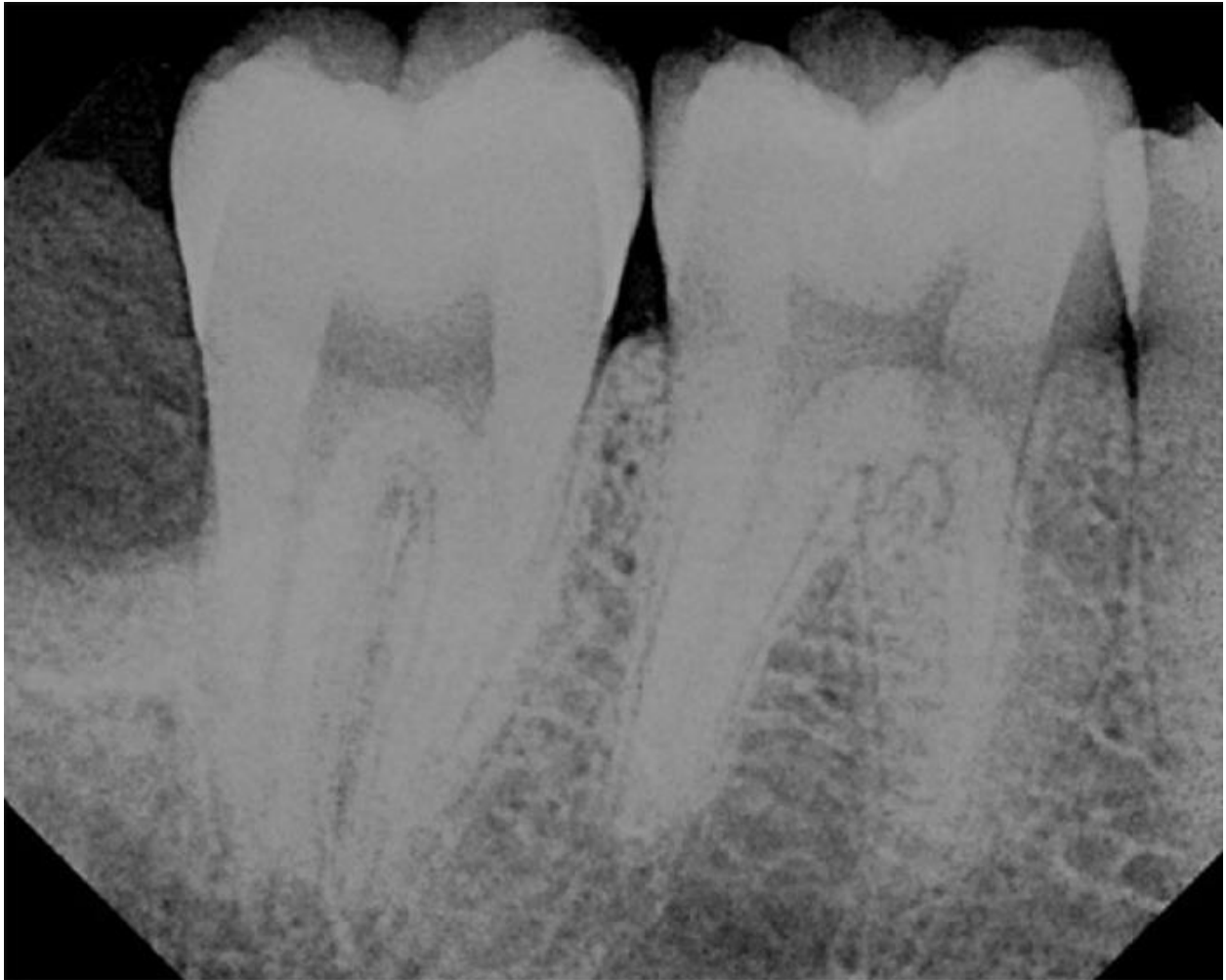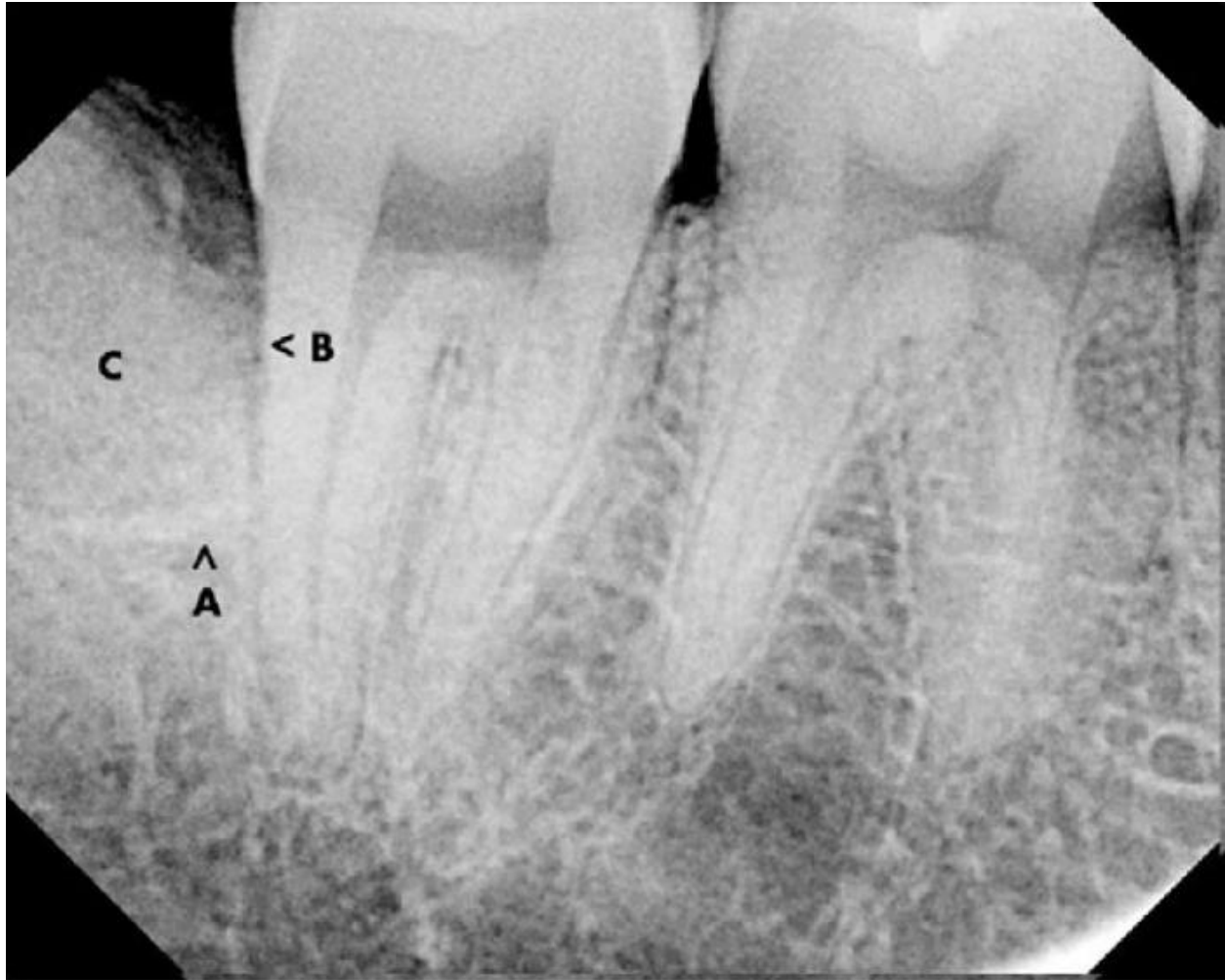


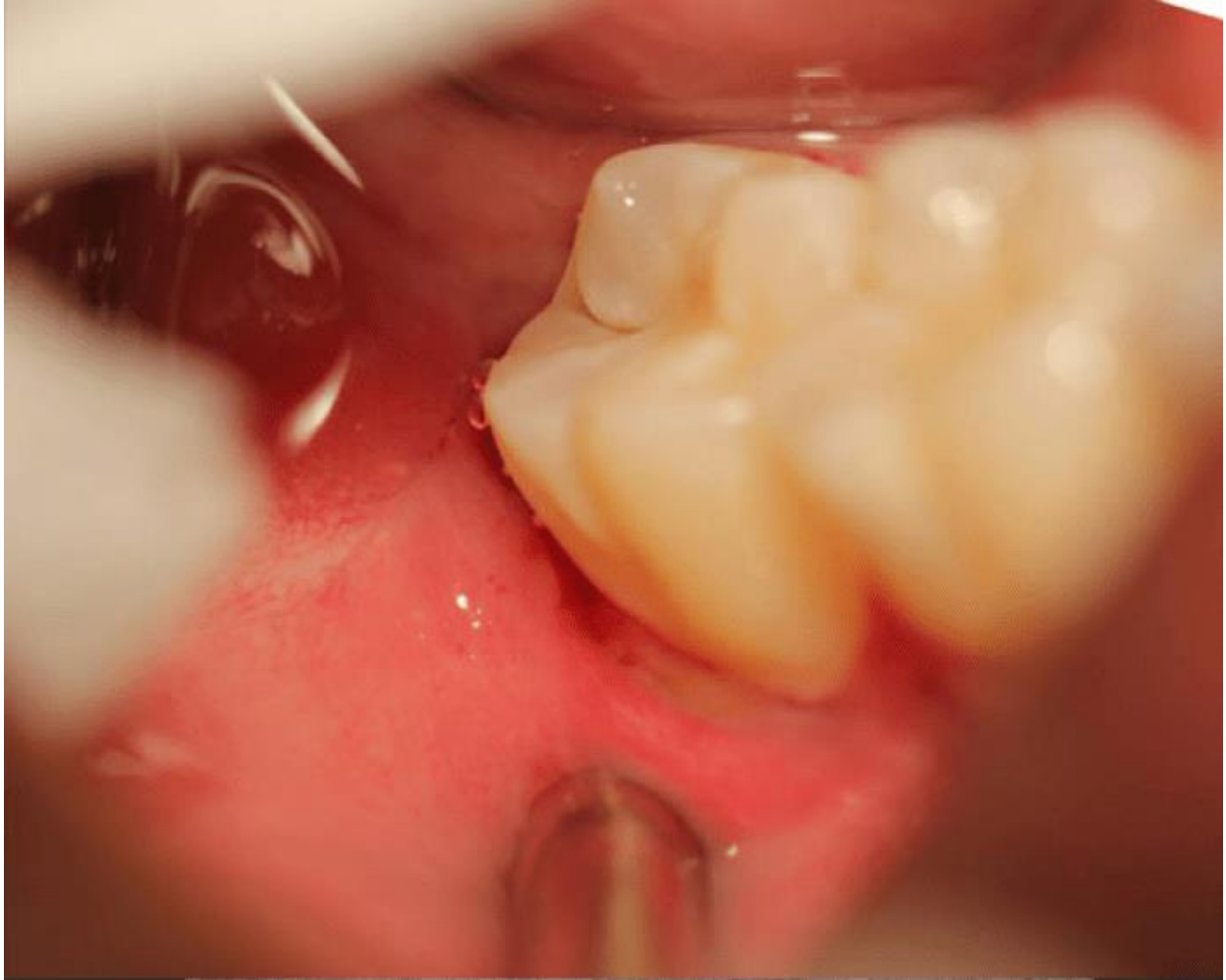Regenerating a Severe Distal Moat with the Inverted Periosteal Graft



This patient presented with a 12mm distal probing #31. The surgical treatment utilized the **Inverted Periosteal Graft**.



6 weeks post op shows the lesion regenerated with a new periodontal ligament. Increased mineralization of the regenerated bone will continue over the next 5 months. (A) Base of original defect. (B) Regenerated periodontal ligament. (C) Regenerated bone. The probings are within normal limits.



6 weeks post op