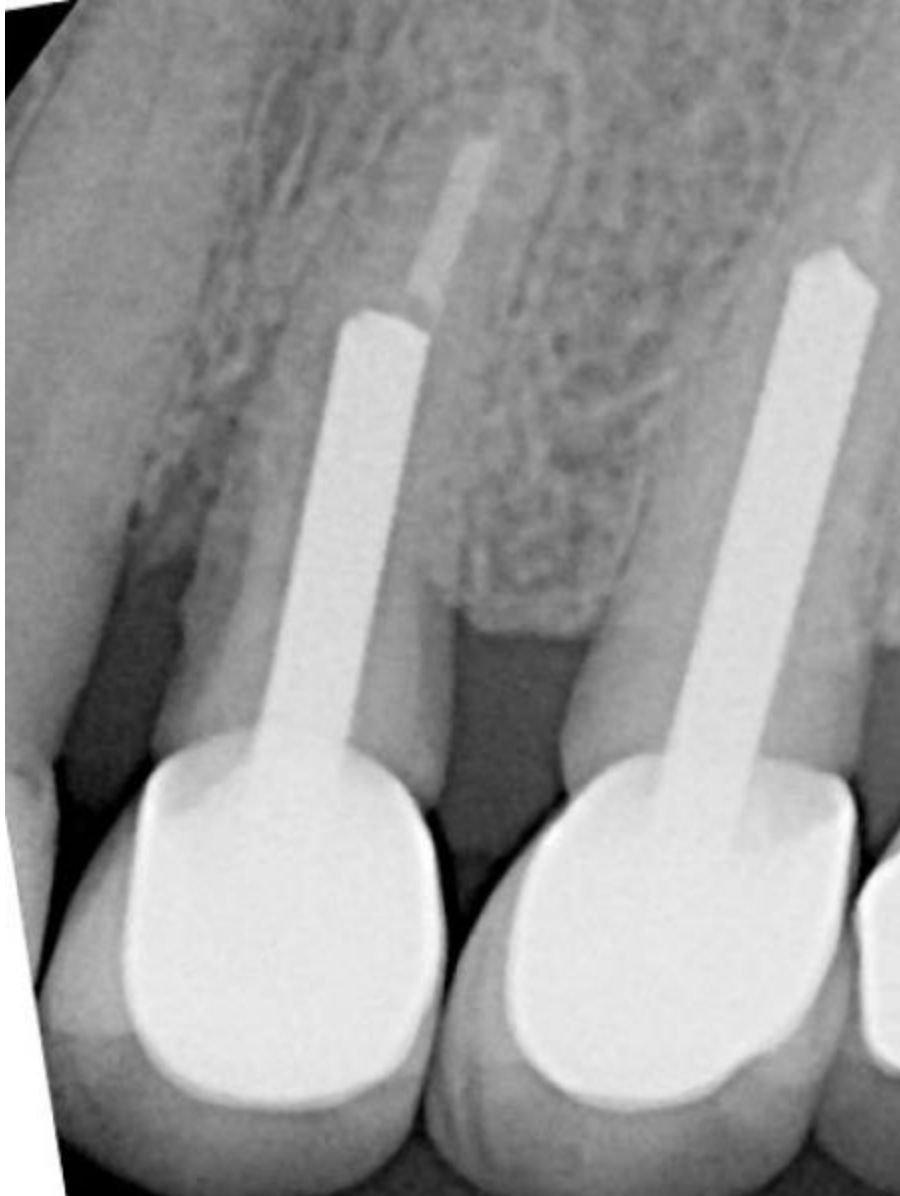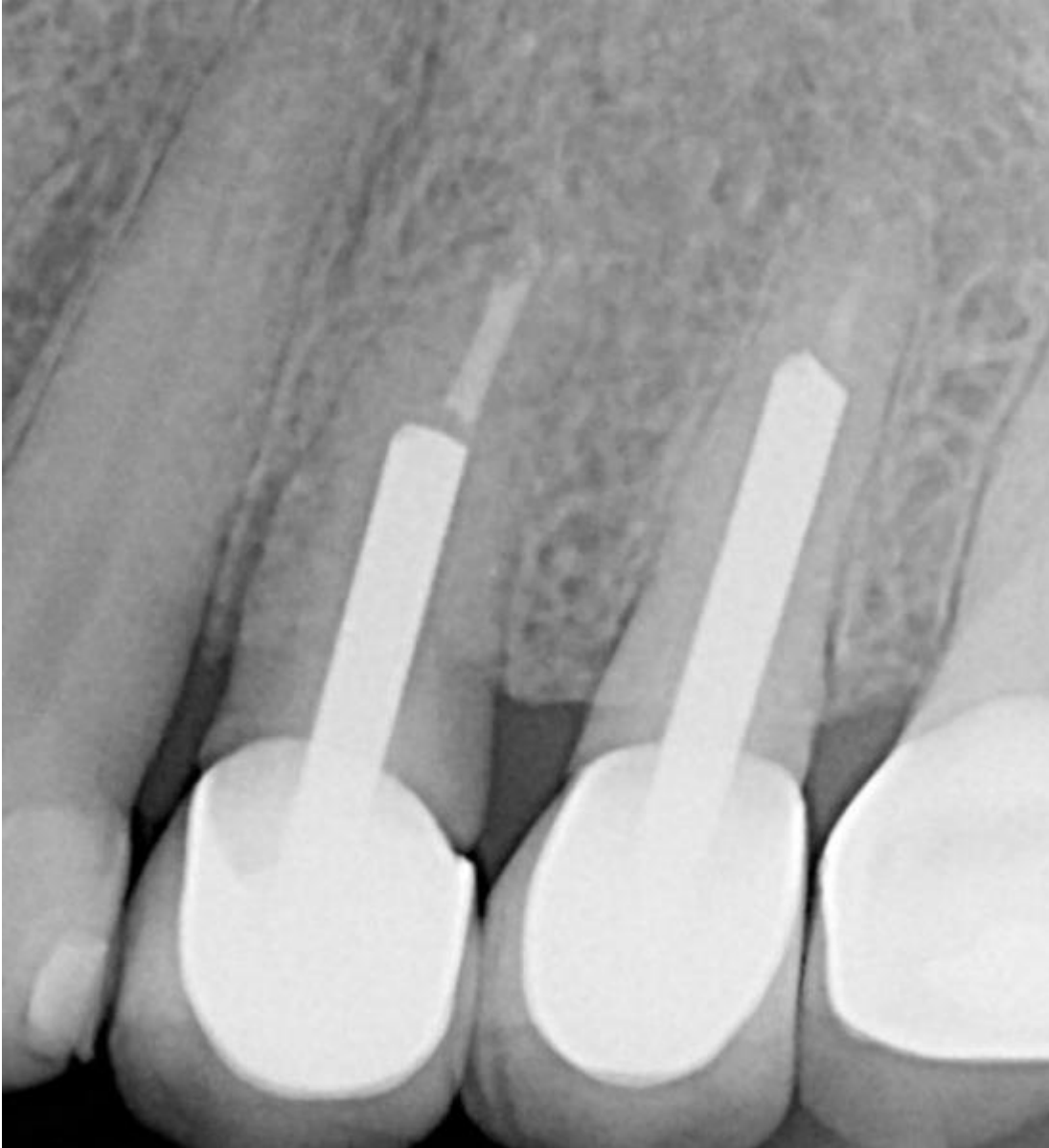


## Regenerating Mesial Furrow Lesion of Maxillary Bicuspid



Tooth #12 presents with a periodontal lesion in the mesial furrow extending near to the extent of the post. The graft material used

was [Immediate Graft™](#) mixed with [OsseoConduct™](#) βTCP Perio granules. The surgery performed, the Inverted Periosteal Graft.



The bone and periodontium has been regenerated on the mesial surface of #12. In time, the periosteum will reduce in width and the bone will increase in width.